



Eye disorders in lesser white-fronted geese (*Anser erythropus*) in captivity

Linnéa Lang

Independent Project • 30 credits

Swedish University of Agricultural Sciences, SLU
Faculty of Veterinary Medicine and Animal Science
Veterinary Medicine Programme

Uppsala 2023



Eye disorders in lesser white-fronted geese (*Anser erythropus*) in captivity

*Ögonproblem hos fjällgäss (*Anser erythropus*) i fångenskap*

Linnéa Lang

Supervisor: Jenny Loberg, Swedish University of Agricultural Sciences,
Department of Animal Environment and Health
Examiner: Hanna Lindqvist, Swedish University of Agricultural Sciences,
Department of Animal Environment and Health

Credits: 30 credits
Level: Second cycle, A2E
Course title: Independent Project in Veterinary Medicine
Course code: EX1003
Programme/education: Veterinary Medicine Programme
Course coordinating dept: Department of Clinical Sciences
Place of publication: Uppsala
Year of publication: 2023
Cover picture: Linnéa Lang
Copyright: All featured images are used with permission from the copyright owner.

Keywords: lesser white-fronted geese, eye disorders, captivity, epidemiology

Swedish University of Agricultural Sciences
Faculty of Veterinary Medicine and Animal Science
Veterinary Medicine Programme

Abstract

Eye problems are common amongst captive birds and become especially problematic in endangered species, such as the lesser white-fronted goose (LWFG). This is the case at Nordens Ark where reoccurring eye problems are seen amongst their breeding population of the species. This study aimed to describe manifestations and investigate possible causes of the eye problems seen within this population. The breeding facility of the Swedish Association of Hunting and Wildlife Management in Öster Malma Wildlife Park, collaborating closely with Nordens Ark and housing birds within the same genetic population, have not detected eye problems in their population. Site visits including keeper interviews were conducted at both facilities to determine differences that could explain the difference in eye problem prevalence. Medical records and general information of LWFG at Nordens Ark with eye problems between 2009 and 2021 were obtained from the medical records system ZIMS to describe the problem using descriptive statistics. Impact of rainfall and temperature on the number of cases per day was investigated using linear regression analysis. The implication of clutch size on the likelihood of a bird obtaining eye problems was also studied using the Chi-square test.

The most common manifestations of ocular disease seen were signs of eye pain, corneal involvement, conjunctivitis, and periocular feather loss. Painful eye problems may negatively impact the welfare of the birds. Cases were almost exclusively observed between May and September and birds under two months were the most affected age group, followed by birds older than two years. No impact from rainfall or temperature on case numbers was found. Regarding management differences between Nordens Ark and Öster Malma, water provision differed most, with Nordens Ark using manually maintained plastic tubs and Öster Malma using concrete pools with constant refill and outflow of water. This, including the fact that clutch size showed a tendency of significance, rose the question if increased stocking density and its negative effects on water quality could increase the incidence of infectious eye problems. To answer this question, and to find significant evidence of the cause of the eye problems seen amongst the LWFG at Nordens Ark, further studies are needed.

Keywords: lesser white-fronted geese, eye disorders, captivity, epidemiology

Table of contents

1.	Introduction	9
1.1	Aim	9
1.2	Questions	10
2.	Literature Review	11
2.1	Introduction to the LWFG and the LWFG Project	11
2.2	Eye disorders amongst captive and wild birds	12
2.3	Possible causes of eye disorders in captive and wild birds	13
2.3.1	Infections	13
2.3.2	Management & environmental factors	16
2.3.3	Deficiencies	18
3.	Material and Methods	20
3.1	Manifestation of eye disorders in LWFG at Nordens Ark	20
3.1.1	Medical information	20
3.2	Husbandry information	22
3.3	Data management	22
3.4	Significance of temperature and rainfall	23
3.5	Implication of clutch size	23
4.	Results	25
4.1	Manifestation of eye disorders in LWFG at Nordens Ark	25
4.2	Husbandry information	27
4.2.1	Nordens Ark	27
4.2.2	Öster Malma Wildlife Park	32
4.3	Significance of temperature and rainfall	36
4.4	Implication of clutch size	37
5.	Discussion	38
5.1	Manifestations of eye disorders in LWFG at Nordens Ark	38
5.1.1	Impact of season and clutch size	39
5.2	Husbandry at Nordens Ark and Öster Malma	40
5.3	Temperature and rainfall	42
5.4	Drawbacks and improvement potential of the study	42
5.5	Conclusion	43

References	44
Popular Science Summary	52
Acknowledgements.....	54

1. Introduction

Different kinds of eye disorders are commonly seen problems amongst birds kept in captivity, likely leading to decreased welfare. However, eye problems may have an even greater impact when they affect populations of species under high threat of extinction, where every individual is extremely important for the survival of the species. This is the case with the lesser white-fronted goose (*Anser erythropus*, LWFG), which is listed as vulnerable (VU) by the IUCN Red List of Threatened Species (IUCN Red List of Threatened Species, 2018). In Sweden, this bird is of great conservational interest as the population has decreased dramatically in Scandinavia in the last century (Andersson, 2011).

Nordens Ark is a part of the so-called LWFG Project, initiated by The Swedish Association for Hunting and Wildlife Management at Öster Malma, and both facilities breed goslings for reintroduction into the wild (Nordens Ark, n.d.). Since several years back Nordens Ark has observed eye problems amongst their population of the species. The problems are seasonal and almost exclusively occur during the summer months. Symptoms vary from mild cases of conjunctivitis and periocular feather loss to more severe cases with birds also showing signs of systemic disease. Even though both Öster Malma and Nordens Ark house geese within the same population, which are related to different degrees, Öster Malma have not seen any eye problems amongst their birds. Although the genetic material is largely shared between the facilities the management and enclosure environments differ.

1.1 Aim

This study aims to characterize manifestation and investigate possible underlying causes of the reoccurring eye problems seen amongst individuals in the population of LWFG at Nordens Ark. The study includes comparisons of management factors, enclosure design, etc. for the LWFG at Nordens Ark with the conditions at the breeding facility of Öster Malma as well as a literature review on the topic. This investigation is conducted to increase the possibility of influencing the welfare of individual birds as well as to give more birds a chance of being reintroduced in the wild to contribute to the survival of the species.

1.2 Questions

- How do the eye disorders of the LWFG at Nordens Ark manifest?
- Can management factors explain the occurrence of eye disorders in the population of LWFG at Nordens Ark?
- Can temperature and/or rainfall explain the occurrence of eye disorders in the population of LWFG at Nordens Ark?
- Does clutch size impact the occurrence of eye disorders in the population of LWFG at Nordens Ark?

2. Literature Review

2.1 Introduction to the LWFG and the LWFG Project

The lesser white-fronted goose is a waterfowl species migrating long distances over the Palearctic region, breeding in the subarctic zone from northern Fennoscandia to eastern Siberia (Jones *et al.*, 2008). It is an herbivorous bird, mainly grazing on green parts of plants (Carboneras & Kirwan, 2020). The birds become sexually mature when around two years old and start breeding between two and three years of age (Andersson, 2011; Carboneras & Kirwan, 2020). The brood size is usually between three to six eggs (Andersson, 2011). Geese spend a large portion of their time in water, exemplified by studies on the snow goose snow geese (*Anser caerulescens*, Frederick & Klaas, 1982).

The IUCN Red List classifies the LWFG as Vulnerable on a global level, and the number of adult individuals is estimated to between 16 000 and 27 000 birds, with a decreasing population trend (BirdLife International, 2018). BirdLife International also ranks the LWFG as “SPEC 1” within Europe, emphasizing that the species is of global interest to protect from extinction (Jones *et al.*, 2008). On a Swedish national level, the bird is categorized as Critically Endangered (SLU Artdatabanken, 2020) and in 2011 the estimated number of birds in the country was as low as 100 birds (Andersson, 2011). According to the same report, this is approximately the same as in the late 80s, despite reintroduction efforts.

Andersson (2011) describes the difficulty to estimate the historical size of the national LWFG population, but states that the number of geese should have been between at least 500-1500 breeding pairs in the beginning of the 20th century, probably more. Between the 1950s and -70s, likely starting even earlier, the Swedish LWFG population went through a dramatic decline in numbers and very few birds remained (Andersson, 2011). However, much thanks to the Swedish LWFG Project and a breeding project situated at Öster Malma, the population was reinforced during the 80s and 90s and the number of LWFG clutches in Sweden has been stable to slightly increasing since the late 90s (Andersson, 2011). Andersson (2011) further describes that since 2005, Russian wild caught LWFG have been the basis for the breeding of LWFG at Nordens Ark, because of the

detection of DNA from the greater white-fronted goose (*Anser albifrons*) within the Swedish LWFG population due to hybridization.

Another report from the Norwegian Ornithological Society estimated the number of breeding pairs in the Norwegian Valdak marshes (an important staging ground for Norwegian LWFG) to 19 adult pairs (Øien & Aarvak, 2006), further underlining the fragility of the Fennoscandian population. In the report, hunting and poaching is stated to be important threats to the LWFG population, as well as the loss of habitats. Typical LWFG habitats such as Arctic open tundras and wetlands (Carboneras & Kirwan, 2020) are altered due to e.g. creation of reservoirs for hydroelectric power in Scandinavian breeding grounds and expansion of agricultural land in wintering grounds (Madsen, 1996).

Hunting pressure on the LWFG is still high along migratory routes in Eastern Europe as well as the Caspian and Black Sea regions according to Andersson (2011). The author also highlights that even in countries where the LWFG is protected by hunting bans, individuals are killed when flying together with flocks of greater white-fronted geese. Through using Barnacle geese (*Branta leucopsis*) as foster parents for Swedish LWFG in the 80s and 90s, the geese were imprinted to use a safer migratory route through the western part of Europe, thereby avoiding countries where the species is hunted (Andersson, 2011). This has resulted in the population being the only western subpopulation that is not decreasing (Andersson, 2011).

The Lesser White-Fronted Goose Project aims to facilitate a viable population of the LWFG in Sweden (Svenska Jägarförbundet, n.d.). The project was initiated in the 70s by The Swedish Association for Hunting and Wildlife Management and is now a collaboration with Nordens Ark as well as Norrbottens Ornitologiska Förening. The work within the project includes captive breeding and reintroduction of LWFG as well as means to decrease disturbance in staging areas, surveillance of the wild population, and actions to inform about the conservation work being done to protect the species (Svenska Jägarförbundet, n.d.).

2.2 Eye disorders amongst captive and wild birds

When it comes to general avian ocular disorders, trauma and infectious diseases are the two most common aetiologies (Moore *et al.*, 2022). When looking specifically at birds maintained in captivity, trauma is much less prevalent and instead, infectious diseases dominate (Moore *et al.*, 2022). Amongst captive birds, and bird species other than raptors, conjunctivitis is the most frequently observed ocular infectious disease (Holmberg, 2008). Signs of conjunctivitis often include ocular discharge, blepharospasm, conjunctival hyperemia, and increased preening (Holmberg, 2008). According to Holmberg (2008), conjunctivitis can be caused by e.g. trauma from foreign bodies, environmental irritants, and infectious agents.

Shivaprasad *et al.* (2022) highlight the lacking literature on eye disorders of the order Galloanserae (fowl), despite the likelihood that ocular disease is as prevalent amongst these birds as other avian species. This is partly since research on birds in the order of Galloanserae often have a flock perspective, rather than focusing on clinical aspects of individual cases (Shivaprasad *et al.*, 2022). Therefore, this literature review will focus on a selection of possible causes of ophthalmologic disease in geese and other waterfowl when possible, with a more general avian perspective when the information on waterfowl is scarce. Reference will sometimes also be given to other vertebrate species.

2.3 Possible causes of eye disorders in captive and wild birds

2.3.1 Infections

According to Moore *et al.* (2022), infectious diseases are the most common cause of ocular disease in fowl, mostly concerning poultry and in conjunction with respiratory disease. When it comes to infectious conjunctivitis, bacteria and viruses are most commonly identified as the cause (Holmberg, 2008).

2.3.1.1 Bacterial diseases

Shivaprasad *et al.* (2022) state that a majority of ocular bacterial infections are an indication of septicaemia or are secondary to viral infection. When it comes to conjunctival bacterial infection, it can be caused by e.g., the spreading of an upper respiratory infection or an opportunistic infection by normal conjunctival flora (Holmberg, 2008). A study by Chalmers & Kewley (1985) demonstrated that *Escherichia coli*, *Staphylococcus epidermidis*, *Klebsiella pneumoniae*, *Micrococcus* spp., α - and non-hemolytic streptococci and *Acinetobacter lwoffii* were the most commonly isolated bacteria from the conjunctiva in clinically healthy ducklings. Some of these bacteria, and others, are listed as conjunctivitis-causing in birds by Holmberg (2008) – *Pseudomonas*, *Staphylococcus*, *Pasteurella*, *Citrobacter*, *E. coli*, and *Klebsiella*.

Mycoplasma spp. is another pathogen sometimes involved in conjunctivitis in birds (Holmberg, 2008) and for example, *M. gallisepticum* and *M. synoviae* have been isolated from waterfowl (ducks) in a study by Bencina *et al.* (1988). However, the ducks in the study did not show any symptoms of disease. Buntz *et al.* (1986) have also isolated *M. gallisepticum* from clinically healthy geese.

Several *Chlamydia* spp. are known to cause symptoms of keratoconjunctivitis in birds, as a part of both local and general presentations of chlamydiosis (Surman *et al.*, 1974). A high prevalence of antibodies of *Chlamydia psittaci*, but low levels of

viable bacteria, has been detected in clinically healthy feral Canada geese (*Branta canadensis*) suggesting that the geese are susceptible to chronic infection (Dickx *et al.*, 2013). Though again, the birds in the study showed no clinical signs at the time of sampling.

Infection by *Actinobacillus suis* has been described to cause conjunctivitis in unusual cases, both in ducks and geese (Hacking & Sileo, 1977; Maddux *et al.*, 1987). Another disease that in rare cases may cause conjunctivitis in birds is avian tuberculosis (Pocknell *et al.*, 1996)

2.3.1.2 Viral diseases

Viral diseases causing eye problems often manifest as conjunctivitis (Shivaprasad *et al.*, 2022). The viral diseases below are all well-known avian pathogens, but new viruses causing ocular disorders are also discovered (Gleeson *et al.*, 2019). The most commonly isolated virus in connection to conjunctivitis in birds is avian poxvirus (Holmberg, 2008).

Avian poxviruses are a group of viruses with variable species specificity causing wart-like lesions on featherless skin (such as eye margin) in birds (Hansen, 1999). Poxviruses are occurring, but are not common, amongst waterfowl and are found worldwide (Hansen, 1999). In an experimental study by Kirmse (1967), ducks and geese were infected with a fowl poxvirus and within two weeks all birds developed non-purulent conjunctivitis, in conjunction with skin lesions on the feet webbing. The conjunctivitis cases seen in the study were completely reversible, with no remaining symptoms after five weeks.

Experimental infection of ducks with different avian influenza virus strains did in some cases cause ocular cloudiness, however, neurological signs and depression predominated (Pantin-Jackwood *et al.*, 2007). Brown *et al.* (2008) infected a few different species of swans and geese with highly pathogenic avian influenza (HPAI), concluding that all birds in the study died except for one cackling goose (*Branta hutchinsii*) and three bar-headed geese (*Anser indicus*). The surviving individuals showed varying degrees of depression and cloudy eyes. Brown *et al.* (2008) concluded that the geese in the study were less susceptible to HPAI than the swans.

Geese infected with Newcastle disease may show ocular signs such as discharge and, in some birds, red and edematous eyelids (Wan *et al.*, 2004). Diarrhea, anorexia, and depression were also seen.

2.3.1.3 Parasitic diseases

Several different parasites have been associated with conjunctivitis in birds, such as *Oxyspirura*, *Thelazia*, and *Cryptosporidium* (Holmberg, 2008).

Oxyspirura mansoni has been described in zoo birds in Malaysia and is dependent on cockroaches as intermediate hosts for reproduction (Vellayan *et al.*,

2012). In the study, ocular oxyspiruriasis manifested as eye scratching, conjunctivitis, cataracts, signs of blindness, eye inflammation, and cloudiness of the cornea. Another species in the same genus, *O. petrowi* has been proven the cause of conjunctivitis, corneal scarring, and keratitis in northern bobwhite quail (*Colinus virginianus*, Bruno *et al.*, 2015). *Thelazia* spp. are species well known to cause eye disease in mammals, however, there are few reports on its significance in birds (Murata & Asakawa, 1999; Brooks *et al.* in Griggs, 2019). *Cryptosporidium* spp. have been isolated from a duckling with histological evidence of conjunctivitis, despite not having any clinical signs indicative of eye disease (Mason, 1986). *Philophthalmus gralli* is another avian ocular fluke, capable of causing conjunctivitis in rheas (*Rhea americana*) according to a case study by (Church *et al.*, 2013).

Natural infection of *Toxoplasma gondii* with ocular manifestations has been reported in for example canaries (*Serinus canaria*, Parenti *et al.*, 1986; Williams *et al.*, 2001). Parenti *et al.* (1986) described an outbreak of toxoplasmosis within a passerine bird farm with an acute presentation of anorexia, diarrhea and dyspnea, and high mortality. Approximately four months after the outbreak, surviving birds within the population obtained signs of ocular disease (conjunctivitis, blepharitis, unilateral ocular atrophy, and chorioretinitis upon ophthalmoscopy). All birds in the study showing gross lesions were seropositive for *Toxoplasma gondii* (Parenti *et al.*, 1986). Williams *et al.* (2001) also report chemosis (in the acute stage) and blindness as symptoms seen in conjunction with a toxoplasmosis outbreak in canaries. Reports on fatal, natural infection of geese with *Toxoplasma gondii* have been presented, however without any clinical signs prior to death (Dubey *et al.*, 2001). Natural toxoplasmosis infection has also been reported in ducks with neurological signs and pasted eyelids (Boehringer *et al.*, 1962).

Out of the parasites described in this section, e.g., *Toxoplasma gondii*, *Cryptosporidium* spp. and certain *Thelazia* spp. are occurring in Sweden (Statens Veterinärmedicinska Anstalt, 2022a; 2022b; SLU Artdatabanken, n.d.-c).

2.3.1.4 Fungal diseases

Amongst fungal diseases affecting avian ocular structures, *Aspergillus* spp. is the most common (Shivaprasad *et al.*, 2022). The species have been isolated from a corneal scraping from a Khaki Campbell duck (*Anas platyrhynchos domesticus*), showing signs of blepharospasm, mildly oedematous eyelids, and epiphora (Sadar *et al.*, 2014). Crispin & Barnett (1978) described cases of *Candida albicans* infection in ornamental ducks, causing thickening, irregularities, opaqueness, and discoloring of the nictating membranes with mild conjunctivitis. One duck in the study showed severe conjunctivitis and mild keratitis including epiphora and blepharospasm from photophobia.

2.3.2 Management & environmental factors

2.3.2.1 Water & water quality

Provision of water and water management is a crucial aspect of waterfowl husbandry (European Committee on Legal Co-Operation, 1999), and may both improve eye health and be a possible cause of eye disorders. O'Driscoll & Broom (2011) investigated if the provision of several different open water sources affected the occurrence of eye problems in ducks, without any significant results. Provision of open water has however in some cases proven to lead to better duck hygiene (such as less dirty nostrils and better plumage hygiene) according to the same study. Jones *et al.* (2009) showed similar findings - ducks provided with open water sources had significantly cleaner eyes and plumage than ducks provided with water nipples only.

While water provision has been proven to improve hygiene, open water may pose a source of bacterial growth from fecal contamination, with negative health consequences for waterfowl (O'Driscoll & Broom, 2011; Liao *et al.*, 2021). Jones *et al.* (2009) showed that plumage, eye, and nostril hygiene was improved when the birds were able to at least dip their heads into the water source and splash their feathers. The authors of this study did not investigate the water quality in the different open water sources, as done in Liste *et al.* (2013). However, while Kuhnt *et al.* (2004 in Rodenburg *et al.*, 2005) showed that despite deep and shallow water sources for bathing contained high bacterial levels and were frequently used, no adverse effects on duck health were seen. Similar results, high bacterial load in water with no health effects, were found by Liste *et al.* (2012; 2013). The increased load of pathogenic bacteria in the water during warmer months has also been demonstrated by Jiang *et al.* (2011) when raising goose stocking density. Even though the study by Jiang *et al.* (2011) did not mention any eye problems, the increased bacterial load during summer months was linked to impaired reproductive performance. In a study comparing duck water provision trough troughs versus waterlines, higher pathogenic bacterial content and higher eye scores (i.e., more signs of eye inflammation) were seen among ducks provided with water troughs (Schenk *et al.*, 2016).

2.3.2.2 Photosensitization

Several types of plants have been described to cause photosensitization lesions in birds. In an article from 1975, it is shown that almost 90 % of a population of geese having ingested bishop's flower (*Ammi majus*) suffered from ocular lesions (Egyed *et al.*, 1975). The geese in the study that developed ocular lesions showed inflammatory signs in the eyes, such as eyelid dermatitis, blepharoconjunctivitis, and keratitis, as well as cicatricial ectropium, symblepharon and ankyloblepharon in the later stages of healing. Periocular feather loss was also seen in the same study.

Besides ocular signs, Egyed *et al.* (1975) also described beak lesions (such as stunted growth of the upper beak) as well as foot lesions (e.g., thickening of the foot web and deformities in the phalanges) in many of the geese. The writers conclude that the severe involvement of the eyes and foot web can be explained by the fact that these body parts are directly exposed to sunlight, therefore being more exposed to the activated photodynamic agent than other parts of the body.

Another study by Shlosberg & Egyed (1978) showed similar effects in ducklings force-fed seeds from longstalk springparsley (*Cymopterus longipes*), i.e. keratoconjunctivitis, periorbital feather loss as well as deformities and other lesions of the beak and foot web. In addition, this experimental study also showed ducklings with blepharospasm, decreased growth rate, and depression. Keratoconjunctivitis and periorbital feather loss was also seen amongst ducklings force-fed with seeds from *Cymopterus watsonii*, as well as scabs on the beak and feet (Shlosberg & Egyed, 1978).

In a clinical report by Rostami *et al.* (2011), perennial ryegrass (*Lolium perenne*) was highly suspected to cause photosensitization in several waterfowl species, including mixed-breed domestic geese (*Anser anser domesticus*). The birds in this clinical report were described to show symptoms of blepharoconjunctivitis and necrotic dermatitis on the eyelids and other parts of the non-pigmented areas of the skin and beak. The enclosure in which the birds were housed was planted with perennial ryegrass prior to the emergence of the symptoms and the symptoms subsided when the birds were moved to another enclosure without the plant in question (Rostami *et al.*, 2011).

Of all the phototoxic plants discussed in 2.3.1.2, not all are found in Sweden. Perennial ryegrass is resident and reproducing in the country (SLU Artdatabanken, n.d.-a), while *Ammi majus* is occurring less frequently (SLU Artdatabanken, n.d.-b). Plants in the genus of *Cymopterus* are native to the western part of North America (United States Department of Agriculture | Natural Resources Conservation Service, n.d.).

2.3.2.3 Climate factors

Different climate factors such as temperature and precipitation may predispose to eye problems, e.g., infections (e.g. Onozuka *et al.*, 2009; Jiang *et al.*, 2011; Ferenczi *et al.*, 2016; Blanchard *et al.*, 2018).

Blanchard *et al.* (2018) showed an indication that an increase in temperature and precipitation led to higher eyeworm reproduction in northern bobwhite quail. Temperature has also been positively linked to parasite prevalence in tropical birds (Zamora-Vilchis *et al.*, 2012). The authors in the study hypothesize that this relation may be explained by the varying occurrence of vectors at different temperatures. The relative risk of *Mycoplasma pneumoniae* pneumonia in humans and temperature have been investigated by Onozuka *et al.* (2009), also showing a significant

positive correlation between the two. High temperatures may also negatively affect the immune system of birds due to inhibition of antibody production and a lower total white blood cell count (Mashaly *et al.*, 2004), therefore possibly making them more susceptible to diseases such as ocular infections.

Regarding precipitation, several pathogens increase in prevalence with increasing rainfall, such as avian influenza (Ferenczi *et al.*, 2016) and certain eyeworms (Blanchard *et al.*, 2018). Conflictingly, no relationship between parasite prevalence and rainfall was seen in the study by Zamora-Vilchis *et al.* (2012). When looking at *Escherichia coli* in river water, increased precipitation was found to also increase the bacterial load in the water (Vermeulen & Hofstra, 2014), possibly causing a greater risk of infection.

2.3.3 Deficiencies

2.3.3.1 Vitamin A deficiency

Hypovitaminosis A may increase the risk of infection and inflammation of the eye, both by directly affecting the eye and vision as well as affecting the immune system. No animal species have the possibility of *de novo* synthesis of vitamin A and rely solely on dietary intake (Blomhoff & Blomhoff, 2006). Vitamin A deficiency in birds can present as swelling of the periocular structures and conjunctiva, including ocular discharge (Beach 1924; Williams 2012). Additional signs of hypovitaminosis A, as described by Williams (2012) are e.g. white plaques in and around the mouth, dyspnoea, and skin- and feather lesions. In rats, it is shown that hypovitaminosis A leads to keratinization of the cornea and conjunctiva, including decreased numbers of goblet cells in the latter (Fujikawa *et al.*, 2003). The changes in the study were largely prevented by the administration of vitamin E. Another study on guinea pigs (*Cavia porcellus*) also demonstrated keratinization of the cornea and the absence of goblet cells following vitamin A deficiency (Pfister & Renner, 1978). Additionally, the study showed hair loss as another result of hypovitaminosis A, which in some guinea pigs was periocular. Pfister & Renner (1978) also describe other ocular signs following vitamin A deficiency, such as squinting and the occurrence of bacteria on the corneal surface upon electron microscopy. This, the authors argue, suggests that damaged corneal epithelium from lack of vitamin A may facilitate bacterial colonization and predispose to corneal ulcers.

Besides possibly causing ocular signs and being important for vision, vitamin A plays a vital role in the function of the immune system in vertebrates. For instance, one study has shown that vitamin A deficiency in rats resulted in e.g. significantly higher white blood cell and lymphocyte count as well as hyperresponsive T-cells, proving that low levels of vitamin A increase clinical manifestations of inflammation (Wiedermann *et al.*, 1996a). It has also been shown that hypovitaminosis A

may increase susceptibility to *Staphylococcus aureus* infection (Wiedermann *et al.*, 1996b).

2.3.3.2 Vitamin E deficiency

Hypovitaminosis E has been linked to, among other disorders, cataract formation in birds. The link between low vitamin E levels in the feed and cataracts has for example been shown in a case study on non-hatched emu chicks (*Dromaius novae-hollandiae*), including other signs such as subcutaneous edema, hemorrhages, and manifestations of myopathy (Crispo *et al.*, 2016). On the contrary, a study on the parakeet auklet (*Aethia psittacula*) at The North Carolina Zoo could not confirm a link between dietary supplementation of vitamin E and the incidence of cataracts within the population (Phillips *et al.*, 2022).

2.3.3.3 Other deficiencies

Several other nutritional deficiencies may have ocular symptoms as a part of their clinical manifestation. Raidal (1995) describes an outbreak of staphylococcal dermatitis amongst commercial Japanese quail (*Coturnix coturnix japonica*) with history, clinical signs, and pathology suggestive of pantothenic acid deficiency. According to the author, the affected quail acquired crusty facial lesions, conjunctivitis, and closed eyelids (some from as early as four days of age), while also appearing generally depressed. A study on White Peking ducks (*Anas platyrhynchos*) also demonstrated dermatosis and ocular exudate in ducklings fed a diet lacking pantothenic acid supplementation (Tang *et al.*, 2020). Other signs of pantothenic acid deficiency described are depression and increased flock mortality (Raidal, 1995; Tang *et al.*, 2020)

Marusich *et al.* (1970) demonstrated that biotin deficiency may also cause ocular signs in poultry, in the form of blepharoconjunctivitis with blepharospasm and eye exudate, among other symptoms.

3. Material and Methods

3.1 Manifestation of eye disorders in LWFG at Nordens Ark

Medical information and general information on the individual birds were used to describe the manifestations of the problems seen amongst LWFG at Nordens Ark. The information was then used to describe the problem using descriptive statistics, to provide an overview of the situation.

3.1.1 Medical information

A summarizing document of every individual LWFG at Nordens Ark that had notes of eye problems between 2009 and 2021 had already been created by medical staff at Nordens Ark. This document was then used as a start off point to backtrack every case to find the original information source as well as gather more information regarding the cases. The original information was obtained from ZIMS (Medical records module as well as Notes & observations in the Animals module), physical medical record copies (from before the change to digital record keeping), keeper reports, yearly reports regarding breeding couples and ring marking of newly hatched goslings from 2014 to 2021. In the documents with information regarding ring marking of newly hatched goslings, it was stated if birds were to be saved for release the following year. Since many goslings with eye problems at the time of release were saved for later release, a sample of these goslings was made using ZIMS to look for notes on eye problems.

ID-number of the birds, age, parental information, and dates were used to couple information found in the summarized document with the original source. A document with a summary of all current and former breeding pairs was utilized in this process. This information was used to couple cases with individuals to obtain complete demographic information on each case.

Information regarding, if available, the date and age when the symptoms were first noted, symptoms, treatment, and outcome were collected, as well as birth date, sex, and parents. All of the above-mentioned raw data was then summarized into

an Excel spreadsheet for further processing, also including the clutch size information described in 3.2.

Data regarding symptoms and treatments were gathered to be used for descriptive statistics, to give an overview of the problems seen and how it has been addressed. This was also done for basic information on each goose. To get a better overview of what symptoms and treatments were most common, the symptoms and treatments were divided into categories (Table 1).

Table 1. Categorization of symptoms and treatments.

Symptom categories	Treatment categories
Unspecified eye problems	None
Eye inflammation	
Eye problem/-s	Unspecified treatment
Conjunctivitis	Systemic antibiotics
Conjunctival hyperaemia	Kesium
Swollen conjunctivae	Bactrim
Protruding third eyelid/tear gland	Noroclav
Conjunctivitis	Synolox
Corneal affection	Topical antibiotics
Grey/white cornea	Ciloxan
Corneal ulceration	Fucithalmic
Keratitis	Terracortil
Corneal oedema	Chloromycetin
Corneal vascularization	Kloramfenikol
Signs of eye pain	Lubricating eye drops/NaCl
Sunken eyes	Lubricating eye drops
Blepharospasm	NaCl
Periocular/facial/unspecified swelling	Topical anti-inflammatories
Unspecified swelling	Voltaren Ophta
Periocular swelling	Yellox
Facial swelling	Isopto-Maxidex
Orbital ring affection	Topical skin treatment
Pale orbital ring	Cortavance spray
Disfigured orbital ring	Silver sulfate
Affected general condition or respiration	Systemic cortisone
Affected general state	
Respiratory signs	
Facial skin affection	
Flaky/dry skin	
Discolored skin	
Skin problems	
Wound around eye	
Epiphora	
Eye pruritus	

- Decreased eyesight
- Periocular alopecia
- Other
 - Ectropion
 - Increased lens opacity
 - Affected pupil reflex
 - Periocular vascularization
 - Iris hyperemia
 - Uveitis

3.2 Husbandry information

Site visits to both Nordens Ark and Öster Malma Wildlife Park was conducted during autumn 2022 to collect information regarding husbandry and management of the respective populations of geese. During each site visit, a tour of the facility where the geese were kept was given. The keepers were asked open questions regarding the management and were allowed to freely describe the husbandry. More specific questions were asked when there was need for clarification. Information gathered from the keepers included a general description of medical problems within the population and routines in the event of sick and/or injured birds. Information on management, enclosure design, cleaning routines (e.g., regarding enclosures and water facilities), feeding regimes, and any changes in these areas throughout the year was also obtained. Lastly, information was gathered on routines specific to the breeding season and care of goslings.

3.3 Data management

One individual could be counted as more than one case if their medical records stated clearly that the individual had recovered completely in between episodes of disease. This was the case for nine birds. The original source was not found in a handful of cases. Some of the medical records were kept at the veterinary department for completion, this information could have been unavailable for this reason. These cases were chosen to be included in the summary regardless. In cases where it was not possible to distinguish how many birds the note referred to the note was counted as one case (e.g., formulations such as “several goslings in pair 18”).

The symptom category “eye problems” was used when this was the only description given, as well as for a few notes when it was impossible to determine what part of the eye was referred to (e.g., “white changes in eye”).

In a document with information on clutches and goslings hatched in 2019, several individuals had notes saying “slightly featherless above the eyes – normal for this stage of feather growth?”. These were chosen not to be counted as cases as the description suggested that the abnormal appearance was due to molting stage.

3.4 Significance of temperature and rainfall

The significance of temperature and rainfall using the number of birds per day registered with eye problems (response variable) was investigated using linear regression analysis in the statistical software program Minitab. The Poisson distribution was used since data were not normally distributed. $\alpha = 0,05$ was considered significant. The birds were divided into temperature and rain classes depending on the mean temperature and total rainfall seven days before disease was noted. The analysis was also done using continuous values on temperature and rainfall. Weather data was collected from the website of The Swedish Meteorological and Hydrological Institute (SMHI). Data on temperature was obtained from weather station Väderöarna A (SMHI, n.d.-a), approximately 26 kilometres from Nordens Ark, and rainfall data were obtained from weather station Heden (SMHI, n.d.-b), approximately 10 kilometres from Nordens Ark. These weather stations were the ones in closest proximity to Nordens Ark with data available from the time frame in question.

Using data from seven days prior to disease being noted was done to minimize the influence of large variations in parameters in single days. Another reason was that weather parameters were assumed to predispose to disease a few days before the outbreak of the disease.

When it comes to the data analysis, similar methods have been used by Blanchard *et al.* (2018). The authors used multiple linear regression analyses to investigate the relationship between average eyeworm count, seasonal temperature, rainfall, and the interaction between temperature and rainfall. However, in this study weather data was only collected from a period of seven days prior to symptoms being noted, as opposed to the 60 days used by Blanchard *et al.* (2018). As the cases in this study were only distributed during the summer months weather data from closer to the disease notion was used to make the data more precise.

3.5 Implication of clutch size

Information regarding the clutch size of every individual was collected through documents with information coupled with the breeding season collected by the keepers. In this document, every individual in every clutch between the years 2014 and 2021 was registered. Cases with individuals that were in or with a clutch at the

time when symptoms were first noted and had symptoms that were detected between 2014 and 2021 were included in the calculations. A chi-square test was performed to determine whether the incidence of eye disease was affected by the number of goslings in the clutch. Again, $\alpha = 0.05$ was considered significant.

4. Results

4.1 Manifestation of eye disorders in LWFG at Nordens Ark

In Figure 1 the most common clinical presentations amongst the birds showing eye problems at Nordens Ark are summarized. The same bird can have several different clinical presentations at once. The symptoms are varied, with signs of discomfort/eye pain, corneal involvement, conjunctivitis, and periocular feather loss dominating.

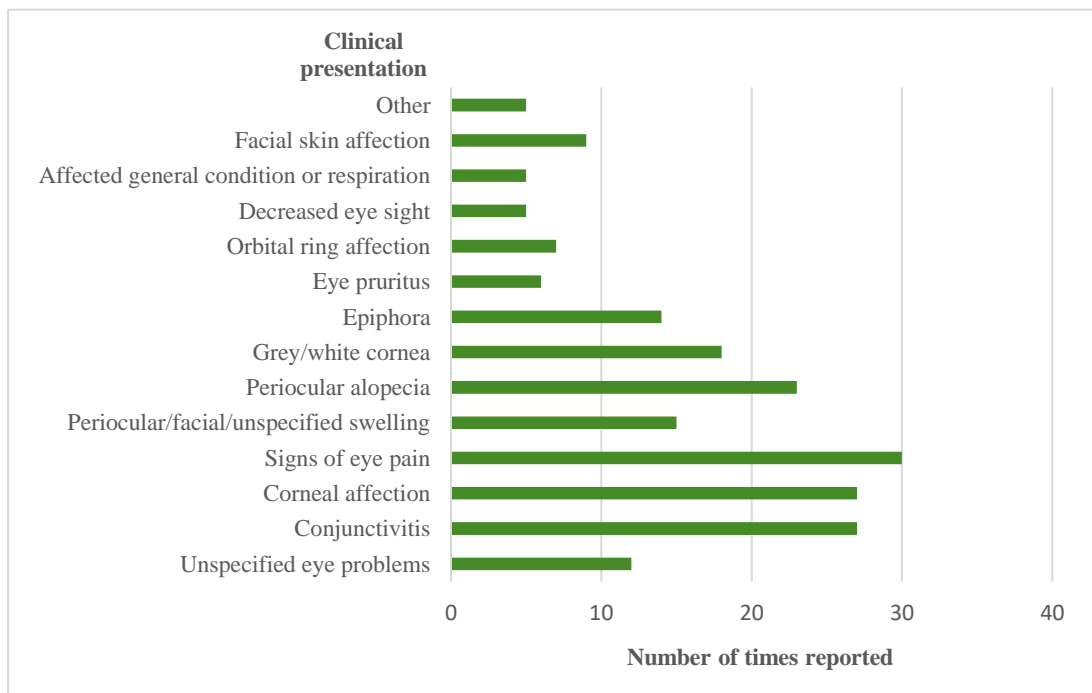


Figure 1. Clinical presentations of the eye problems seen amongst LWFG at Nordens Ark divided into categories and how many times they were reported. n = 75.

The most used descriptions of the eye problems found in the medical records were, in falling order, blepharospasm, periocular feather loss, conjunctival hyperaemia, and some degree of grey- or whiteness in the cornea.

The most commonly affected age group was birds below two months of age. After that age, the incidence is markedly lower, with a slight increase again amongst birds over 24 months of age (Fig. 2 a). Note that it is possible for the same bird to acquire eye disease several times at different ages. Cases almost exclusively occur between May and September, with a few single cases being reported from other times of the year (Fig. 2 b). Regarding the sex distribution among the cases, 24 were female, 24 were male, and 10 were undetermined.

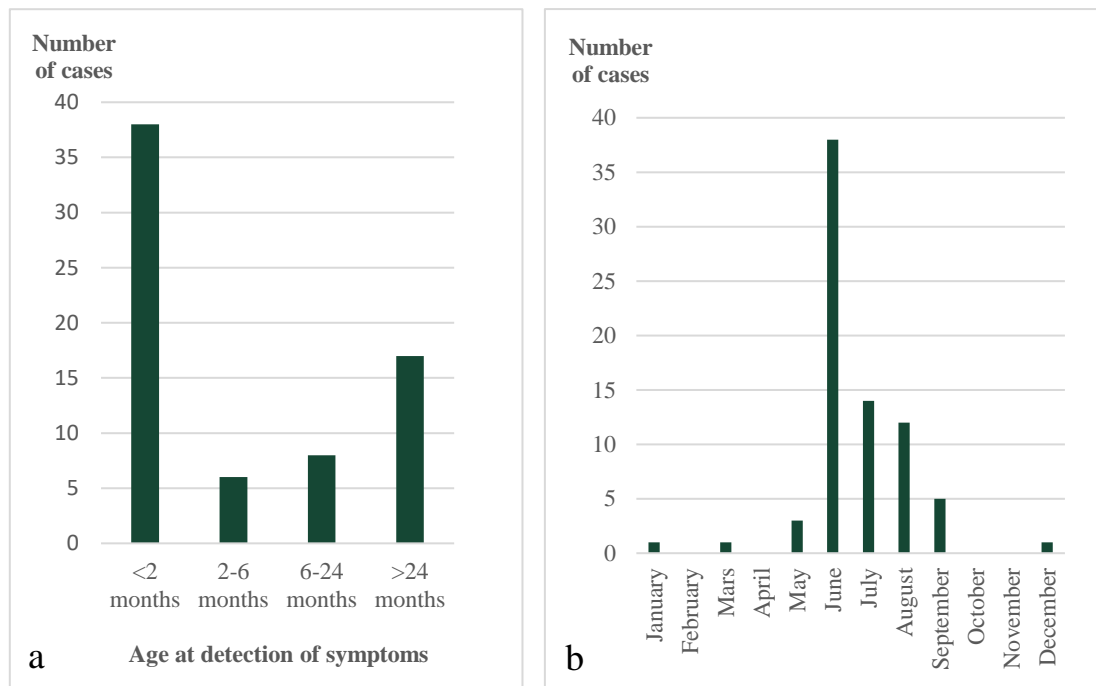


Figure 2 a-b. Number of cases divided over the age at the time when symptoms were first noted (a, $n = 69$) and the number of cases throughout the months of the year (b, $n = 75$).

Figure 3 gives a summary of how many times different treatment categories were used, as well as dividing the recovery success of birds in each category. Several different treatment types can have been used in one single case. If a bird was treated using the same treatment on several occasions, it was only counted once. Out of the 75 cases found, 22 recovered completely, 13 recovered partially and four birds were euthanized (out of which two were due to stress from blindness). 36 of the cases had no follow-up information and the outcome in these cases is therefore unknown.

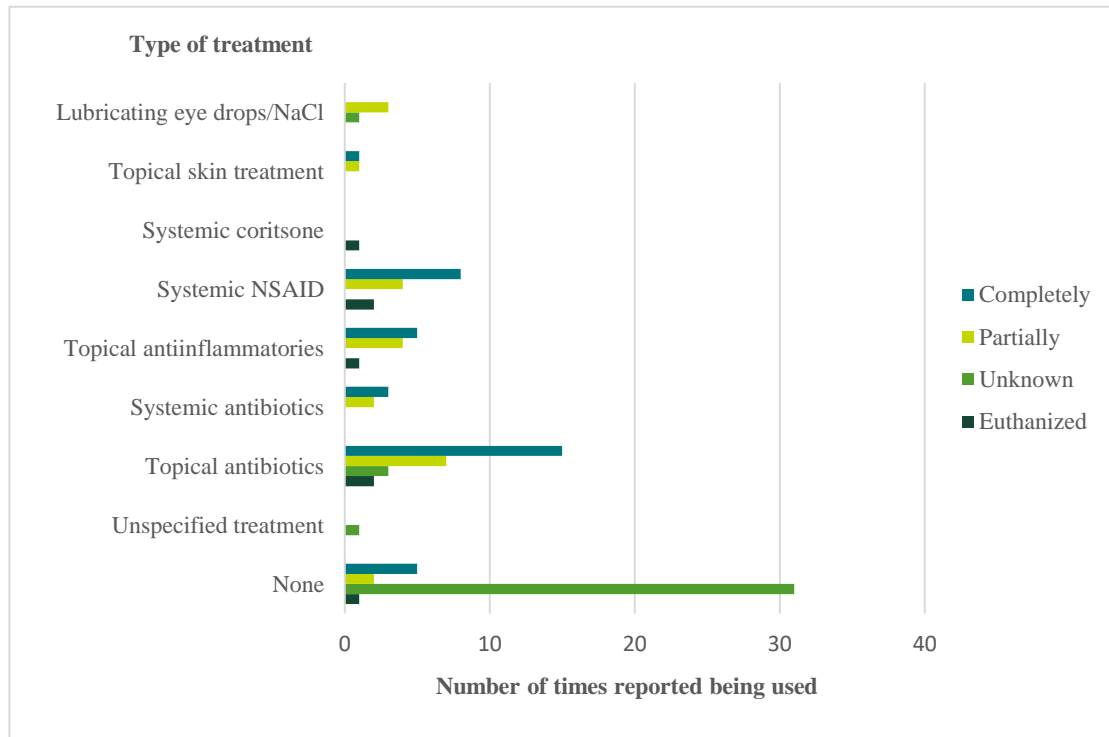


Figure 3. The number of times different treatment types were used and the outcome per treatment type (outcome explained to the left in the diagram), $n = 75$.

4.2 Husbandry information

Below the general management of the geese at Nordens Ark and Öster Malma is summarized respectively, as described by the responsible keepers at each facility.

4.2.1 Nordens Ark

Nordens Ark started collecting wild LWFG from Russia for breeding purposes around 2005-2006. Today approximately 50 birds are held at the facility, up to around 100 birds including goslings during the breeding season. The keepers caring for the LWFG are part of a team responsible for caring for all the birds in the park.

4.2.1.1. Monitoring and health issues

The keepers have witnessed eye problems amongst the geese for several years, always during the summer months. It usually starts with the bird's eye getting slightly red and the bird starting to squint, to palpebral and conjunctival swelling and periocular alopecia (Fig. 4 a-d). The keeper mainly responsible for the LWFG has gotten increasingly skilled at detecting the cases over the years and has also trained the other keepers to do the same. The bird's eyes are watched with

binoculars during the summer season almost every day to detect any suspicious birds for catch-up and control. If the case is bad enough the on-site vet is involved and sometimes the keepers just rinse the birds' eyes with saline to mitigate the problem



Figure 4 a-d. Examples showing geese with periocular swelling, alopecia and/or conjunctival hyperemia in goslings (a, b) and adults (c, d). Photo: Elin Byröd and Michelle Kischinovsky.

4.2.1.2 Water and food provision

In the outside enclosure, water is provided in several 60-liter plastic tubs. The water in these is manually dumped out into the outside enclosure and then refilled once daily outside of breeding season (Fig. 5). During the breeding season, birds are kept in breeding pairs and are then provided with one 60-liter tub per pair. When the pair has goslings the water in these is changed twice daily to try and mitigate the occurrence of eye problems. During summertime, many insects gather around the tubs. The tubs are pressure washed once a week for thorough cleaning. Drinking water is also provided in a few separate water dispensers, in which water is changed daily when all the birds are housed together. When the birds are housed indoors water is provided in four large concrete pools (Fig. 6), which are emptied through an inbuilt drain and refilled manually once a day.



Figure 5. Tubs for water provision in outside enclosure, approximately six hours after cleaning and water change. Photo: Linnéa Lang.



Figure 6. Concrete pool for water provision in inside enclosure during the colder months. Photo: Linnéa Lang.

A basic maintenance pellet for ducks, geese, and swans (Garvo International, n.d.-a) is provided as the only feed outside of the breeding season and the birds are phased over to a waterfowl breeding pellet from the same company (Garvo International, n.d.-b) a couple of weeks before being separated into breeding pairs. Pellets are continuously refilled in roof-covered trays in the outside enclosure (Fig. 7), which are cleaned if soiled or if pellet residue gets wet and soggy. During wintertime, when the birds are housed indoors, they are also provided with lettuce lowered into the pools using bolts (to facilitate natural foraging behavior) and carrots.



Figure 7. Part of the outside aviary showing a roof-covered pellet tray and a dispenser for drinking water (white). Photo: Linnéa Lang.

4.2.1.3 Enclosures

The geese are mainly kept in an off-exhibit part of the park. Here the outside enclosure consists of two aviaries with sides secured into the ground in hard plastic with a roof consisting of a relatively small masked netting to keep birds of prey out. The birds are wing clipped after molting during the autumn, to ensure none of them accidentally fly into the net, risking hurting themselves in the process. The same material as the sides are made of is also used as sight barriers and dividers for inside the aviary (Fig. 8, 9). The outsides of the aviary sides are lined with electric wires. The ground in the aviaries consists of grass which is trimmed regularly to be kept short during the summer. During the breeding season, the outside aviaries are divided into separate sections for each breeding pair, using the sight barriers men-

tioned. See Figures 8 and 9 for more pictures of the principal design of the outside enclosure.



Figure 8. Parts of the outside aviary with sight barriers/dividers in green. Photo: Linnéa Lang.



Figure 9. Parts of the outside aviary, showing the ability to create smaller enclosures within the aviary during breeding season. Photo: Linnéa Lang.

When the water in the outside tubs starts to freeze the birds are moved to the indoor enclosure fitted with four of the large concrete pools mentioned in 4.2.1.2, divided into two parts by a low wall. The substrate used is wood shavings and straw. Sight

barriers in the form of sectioned plastic curtains are hung both at floor level and in the pools. Once the birds are moved inside the interior of the indoor area is not changed, since the birds react adversely to a changing environment according to the keepers' experience. If the weather allows, the birds are given the opportunity to go out into one part of the outside enclosure during the day, even in wintertime.

4.2.1.4 Breeding season

Around the 1st of April, the established breeding pairs are moved out to their respective separate enclosures in the outside aviary. Nordens Ark can house up to 13 breeding pairs at once, with up to around seven goslings each. The pairs are separated to ensure that dominant females do not steal goslings from less dominant females and to ensure the parents of the goslings can be determined for the breeding program. Birds not in a pair during this time are moved down to a public viewing part of the park, such as adult birds not having found a mate and younger birds. Lately, however, these have also been kept in the breeding facilities due to predators sighted in the public area.

The female roosts for around 25 days and the goslings hatch from roughly the middle of May until the middle of June. If the female abandons any eggs these will be hatched in a hatching machine. The goslings hardly swim anything the first 2-3 weeks and then gradually start to swim more and more. Ramps are used up to the tub's rim as well as down into the water to minimize the risk of goslings drowning because they cannot get out of the water. The goslings are fed insects during their early days and gradually transition to foraging more grass as they age. Subjectively, the mortality amongst the birds is low according to the keepers.

The goslings are released to the wild at around 38-40 days of age before they learn to fly at around 43 days old. This is to avoid them escaping the release site too soon and not finding their way back.

Once the goslings are released the birds are once again kept in two bigger breeding groups, ensuring related birds do not form pairs. If a pair is not breeding as intended, they can be sent to Öster Malma and vice versa, in order to try creating new breeding pairs.

4.2.2 Öster Malma Wildlife Park

Öster Malma Wildlife Park is the breeding facility where The LWFG Project was initiated in the 1970s. Today they collaborate with Nordens Ark to breed birds to be released into the wild. They usually hold around 10-20 adult LWFG. At its maximum, the number of birds, including goslings, runs up to approximately 45-50 birds. The project manager for the LWFG Project, situated at Öster Malma, was just recently assigned the position. The keeper primarily caring for the geese has also recently started their employment.

4.2.2.1 Monitoring and health issues

The keepers cannot recall ever having LWFG with eye problems (or any other bird on the premises for that matter). The most common reason for contacting the veterinarian collaborating with the park is lameness.

4.2.2.2 Water and food provision

Water is provided through large concrete pools which are fitted with a constant water supply from a nearby lake with water of drinking quality (Fig. 10). The water is not filtered or treated in any way before being pumped into the pools. Water is also constantly drained from the pools, ending up in the sewer, creating a constant flow of water. In the summertime, some of the water is collected to reuse for lawn watering in the enclosure. The pools are emptied and cleaned of debris about once a week. During the winter and other non-reproductive months, the geese are fed the same maintenance pellets as the LWFG at Nordens Ark, in several feeding trays situated throughout the enclosure, fitted with roofs to avoid contamination from wild birds (Fig. 11). During the breeding season, the same breeding pellets used at Nordens Ark are also used at Öster Malma.




Figure 10. Setup of the concrete pool in the enclosure. Photo: Linnéa Lang.



Figure 11. Design of the pellet feeding trays. Photo: Linnéa Lang.

4.2.2.3 Enclosures

The birds are housed in an outdoor aviary all year round since the birds expressed a strong stress reaction when the staff tried housing them inside during the winter months a few years back. Instead of being housed indoors, the birds are provided with an area within the aviary with plenty of straw that is also fitted with a heat lamp in wintertime (which the birds hardly ever use). The aviary consists of a relatively fine masked net as a roof and metal fences on the sides and grass-covered grounds (Fig. 12).



Figure 12. Design of the enclosure. Photo: Linnéa Lang.

The birds are wing clipped to mitigate the risk of them flying into the netting. Despite the relatively fine masked netting wild birds, such as stares, readily enter the aviary and eat pellets from the geese' feeding trays. The holes in the net are however small enough to keep any birds of prey out. The aviary has not been changed since Öster Malma started housing LWFG, except for an extension to the lower part of the aviary built to offer more browse, which is largely unused by the birds.

4.2.2.4 Breeding season

In springtime, around mid-April, the birds are separated into their preferred pairs for breeding and each pair gets its own enclosure in the upper part of the aviary. The lower part of the aviary can also be divided into pairwise enclosures as needed. Some of these enclosures have natural hiding places, such as shrubbery, while others are fitted with hiding spaces as needed if the enclosure is considered too barren. In spring and summertime during the vegetative growth season, the grass and weeds are trimmed short regularly in the aviary to facilitate foraging behavior. However, when the female roosts, the trimming is not performed to avoid disturbing the nesting female. During the breeding season the geese are fed the same type of breeding pellet as is offered the LWFG at Nordens Ark. When the goslings have hatched, they are fed insects on a platter, which is also covered by a small roof structure to avoid attracting wild birds.

The goslings are transported to the release site together with the goslings from Nordens Ark when they are of sufficient age. After this, the parents are once again kept together in one whole group. If a gosling is unfit to be released it is transported to Nordens Ark to either become a breeding bird or to be saved for release the following year (i.e., no "spare" birds are saved at Öster Malma).

4.3 Significance of temperature and rainfall

There were no significant correlations between the number of birds per day with detected symptoms and precipitation in mm rainfall seven days before detected symptoms (Fig. 13; Chi-square = 0.02; $p = 0.88$).

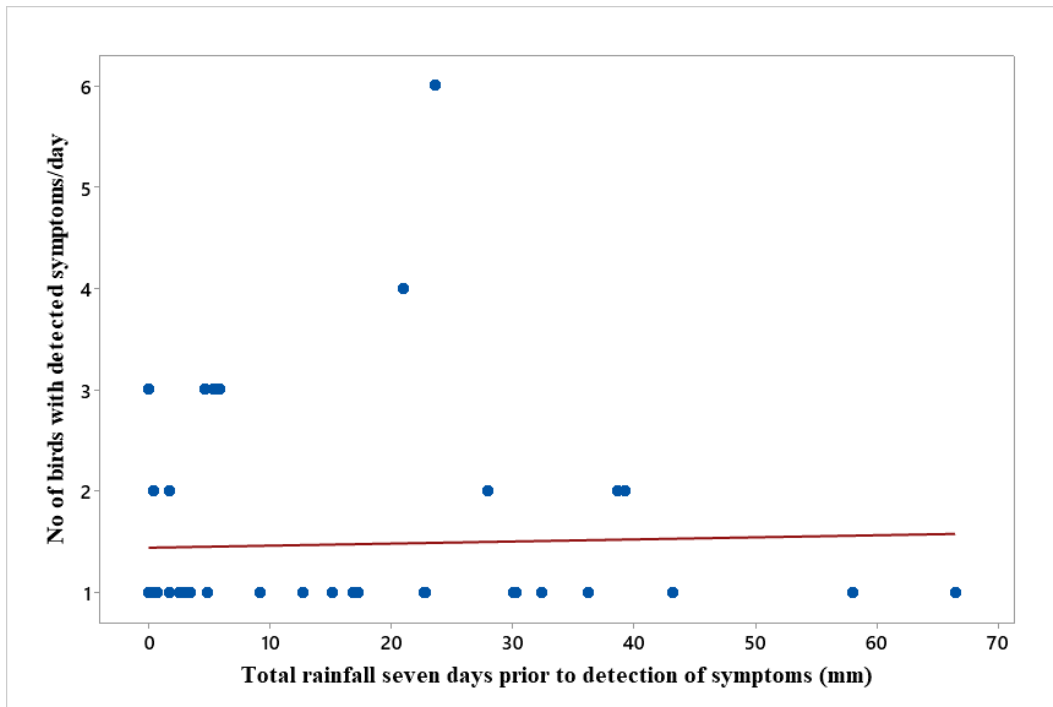


Figure 13. Scatterplot of the number of birds with detected symptoms per day vs total rainfall seven days prior to detection of symptoms, in mm. Linear regression fit included. $n = 66$.

Likewise, no significant correlations were found between the number of birds per day with detected symptoms and mean temperature in degrees Celsius seven days before detected symptoms (Fig. 14; Chi-square = 0.05; $p = 0.82$).

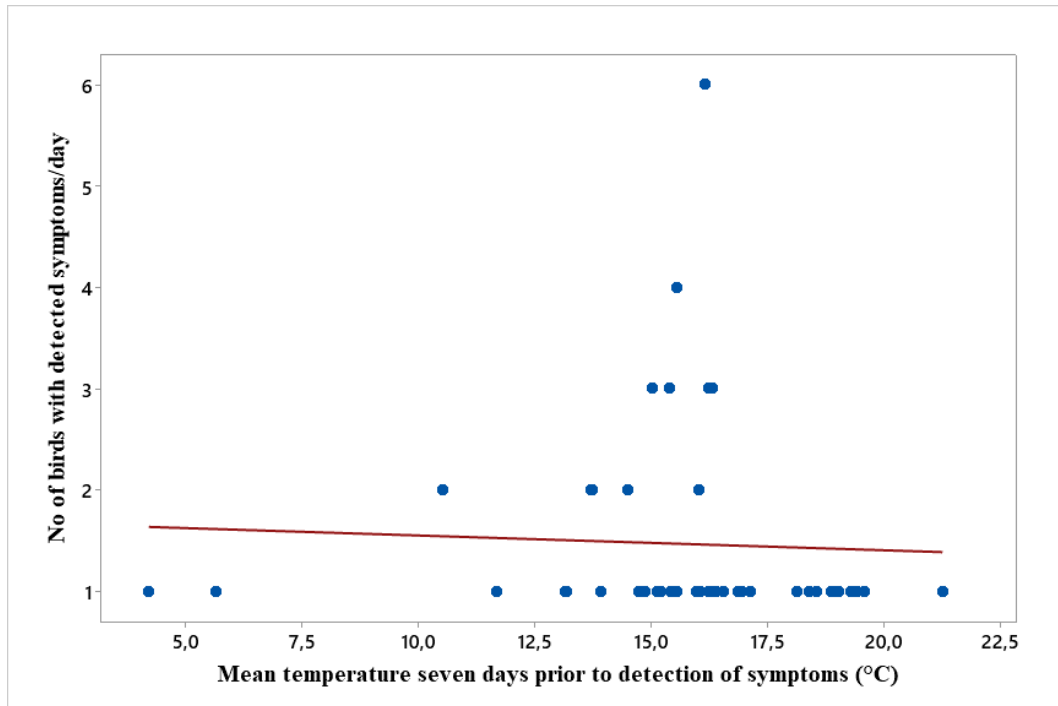


Figure 14. Scatterplot of the number of birds with detected symptoms per day vs mean temperature seven days prior to detection of symptoms, in degrees Celsius. Linear regression fit included. $n=66$.

Correlation between the same factors was also tested with temperature and precipitation divided into classes, using the same method as above. No significant results were found.

4.4 Implication of clutch size

The impact of clutch size on whether a bird shows symptoms of eye problems or not showed tendency of significance (Chi-square = 13.05; $p = 0.07$), albeit the p -value is still over 0,05.

5. Discussion

This study aimed to investigate possible underlying causes of the reoccurring eye problems seen amongst individuals in the population of LWFG at Nordens Ark, including comparisons with the breeding facility at Öster Malma Wildlife Park. These questions are elaborated upon in the following discussion, including possible implications for the geese at Nordens Ark as well as notes on the study itself.

5.1 Manifestations of eye disorders in LWFG at Nordens Ark

In this study, the manifestations of the eye problems seen within the LWFG population at Nordens Ark were described. One could conclude that many of the described signs are indicative of conjunctivitis. In the literature review, possible causes of conjunctivitis are listed, such as trauma from foreign bodies, environmental irritants, and infectious agents (Holmberg, 2008). Photosensitization has been described to cause conjunctivitis (Egyed *et al.*, 1975; Shlosberg & Egyed, 1978; Rostami *et al.*, 2011), but may be deemed a less likely cause for the birds at Nordens Ark since other nonpigmented areas of the body such as the foot web is usually also affected. As infectious diseases are the most common cause of ocular disease in fowl (Moore *et al.*, 2022), one could argue that it is a likely cause of the problems seen at Nordens Ark. E.g. bacterial infection with *Chlamydia* spp. may lead to involvement of both the conjunctivae and cornea (Surman *et al.*, 1974), which was commonly seen in the current study. Viral infections also often manifest as conjunctivitis (Shivaprasad *et al.*, 2022), but many of the viruses described in the literature review readily show other predominant signs such as neurological signs (Pantin-Jackwood *et al.*, 2007) or gastrointestinal signs (Wan *et al.*, 2004). Although bacterial infection seems to be a likely cause of the eye problems amongst the LWFG in the study, one should keep in mind that it is not possible to determine the underlying cause of the problem solely from the clinical presentation.

Besides signs of conjunctivitis, corneal affection, signs of pain from the eye, and periocular feather loss were also relatively common. Since signs of pain originating from the eye (e.g., squinting) is a very common manifestation, one can conclude that the problems seen result in a direct impairment of the individual bird's welfare.

In a few, but serious, cases when the eye disease has led to blindness in the affected eye, birds even had to be euthanized due to severe stress behavior. The five domains model within the animal welfare field highlights the importance of the animal's perception of its situation. The first four domains ("Nutrition", "Environment", "Health" and "Behaviour") and compromises in these can accumulate in anxiety, fear, pain, or distress, making up the fifth domain "Mental State" (Mellor & Reid, 1994). From the perspective of this welfare model, one can certainly argue that pain from an eye disease or distress from altered sight in severe cases, deteriorates the welfare of affected birds. Every LWFG having to be euthanized is also a great loss for the already fragile and limited breeding population.

Concerning the corneal manifestations, many of the reports regarding problems affecting the cornea included descriptions of white and grey changes in the cornea in seemingly unaffected birds. In some cases, the changes were described as "reversible" and seem to have been quite common. Corneal ulceration also occurred, but to a lesser extent than these color changes. As for the periocular feather loss, similar signs have been described in conjunction with e.g., photo-toxicity (Egyed *et al.*, 1975; Shlosberg & Egyed, 1978) and nutritional deficiencies (Pfister & Renner, 1978).

Treatment regimens varied greatly, and no clear patterns were seen in recovery with regard to treatment type. Topical antibiotics seem to have been used the most when opting for treatment, however choosing not to treat seemed to be the most common option. A high number of cases that were not treated were also not followed up which makes concluding the matter difficult. No sex predisposition was detected in the study.

5.1.1 Impact of season and clutch size

A very clear seasonality in the problems was seen as almost all cases were registered between May and September. This could indicate that the problem is worsened by warmer weather. Another aspect changing in the population during this time of year is the fact that it is the breeding season. Pairs are divided into separate enclosures with their hatchlings and share one tub for swimming and drinking, which could lead to more faecal contamination of the water. In this study, clutch size showed a tendency of having significant impact on the risk of acquiring eye problems ($p = 0.07$). Thus, it could be argued that an increase in clutch size, and therefore stocking density, may lead to a higher risk of obtaining (infectious) eye problems due to more faecal contaminants in the water.

Although, it was difficult to draw conclusions from the obtained data regarding in what way clutch size impacted eye problem occurrence. With a larger number of cases, this trend may have been clearer. Clutch size impact does however tie into the concept of higher stocking density leading to a higher infection pressure and negative health effects, as described by e.g. Jiang *et al.* (2011). In the study by Jiang

et al. (2011) the stocking density was however much higher than at Nordens Ark, including that fish were also kept in the same ponds as the geese, possibly limiting the extent to which the results from that study can be extrapolated. Schenk *et al.* (2016) also showed that open water sources (troughs) resulted in a higher pathogenic bacterial count and a higher incidence of signs indicative of eye inflammation in ducks, further supporting the argument that soiled water may cause eye disorders. Besides resulting in direct adverse health effects, lipopolysaccharides from gram-negative bacteria have been shown to affect the immune function in birds (Star *et al.*, 2007), possibly increasing the risk of acquiring ocular infections.

One could also support the hypothesis on stocking density negatively impacting water quality by looking at the situation at Nordens Ark during wintertime. The indoor concrete pools at Nordens Ark appeared to be vastly larger in volume compared to the outdoor tubs which, together with a lower stocking density during the winter (goslings are reintroduced to the wild during the summer), may result in a decreased bacterial load and less chance of the birds acquiring infectious ocular diseases during the wintertime. Despite many arguments supporting this hypothesis, some studies have investigated the influence of contaminated water sources and their effect on waterfowl health without any adverse findings (Kuhnt *et al.*, 2004 in Rodenburg *et al.*, 2005; Liste *et al.*, 2012, 2013). This emphasizes that it is somewhat unclear whether there are negative health effects of a high bacterial load in the water, even though it has been shown in some studies. It should also be considered that a large portion of the literature cited is referring to waterfowl kept for the production of products of animal origin (e.g., Jones *et al.*, 2009; Jiang *et al.*, 2011; O'Driscoll & Broom, 2011) and therefore conditions (such as stocking density and housing design) may be vastly different from wild animals kept in a zoo setting, further limiting the extent to which conclusions can be drawn.

The most affected age group was birds under two months of age, followed by birds over two years of age. If one argues that the problems are predisposed by being in a clutch setting, the fact that birds over two years of age are often affected could be explained by them being sexually mature after that time (Carboneras & Kirwan, 2020). This could mean that birds over two years of age are more likely to have goslings themselves and therefore be more exposed to soiled water. The trend of the young being affected to a higher degree than the adults could possibly be explained by the more novel immune system amongst the goslings.

5.2 Husbandry at Nordens Ark and Öster Malma

Since birds at Öster Malma are of the same genetic background as the LWFG at Nordens Ark, but eye problems are only evident in the latter facility, it is interesting to compare management factors between the two. The facilities show many simi-

larities in their management, such as feeding regime and care during the breeding season, but with a few larger differences worth mentioning.

Firstly, at Öster Malma the birds are housed outdoors all year round while at Nordens Ark the geese are kept indoors during the colder months. This however is likely not influencing the incidence of eye problems since the problems are pretty much exclusively seen during the summer. Secondly, the system for water suppliance is vastly different. At Nordens Ark 60-liter plastic tubs are manually emptied, cleaned, and refilled daily while at Öster Malma, a system that constantly fills and drains large concrete pools is used. At the same time, Öster Malma is also usually housing fewer geese than Nordens Ark. One could assume that the stagnant water in a tub plus a higher stocking density may result in a higher bacterial load in the water during a warm day, once again tying in to the reasoning in section 5.1.1. A study by Lipphaus *et al.* (2014) showed that microbial growth in water samples from household taps was significantly increased in stagnant water when compared to after the taps being flushed, especially in higher temperatures. This would support the argument that the constant water flow in the pools in Öster Malma decreases bacterial growth in the water, thus possibly leading to a lesser risk of eye infections. The role of temperature in bacterial growth in water (Jiang *et al.*, 2011; Lipphaus *et al.*, 2014), coupled with the tendency of clutch size impacting eye disorder occurrence (see section 5.1.1.), could add to the explanation of why cases are seen mainly during the warmer summer months.

Another key difference in management between Öster Malma and Nordens Ark is surveillance. The meticulousness in eye health surveillance of the keeper responsible for the LWFG at Nordens Ark may influence the number of affected birds detected. However, even if this may be true for more subtle signs of ocular disease, one could argue that more severe cases would also have been noted at Öster Malma should there have been any.

When it comes to food, two different aspects that can affect eye health in birds have been discussed in the literature review – photosensitization from toxic plants and nutritional deficiencies. Plant population in the enclosures was not investigated within the frames of this study, although plants proven to be phototoxic with effects on the eyes of birds (Rostami *et al.*, 2011) do exist in Sweden (SLU Artdatabanken, n.d.-a). The symptoms of rye grass photosensitization seen by Rostami *et al.* (2011) do appear somewhat similar to some of the ones seen at Nordens Ark (e.g., conjunctival hyperemia and periocular feather loss), However, other symptoms described by the authors differ vastly from the symptoms of the LWFG at Nordens Ark, such as beak deformities and foot web lesions, deeming this a less likely cause of the eye problems in this particular case. Besides plant toxicity, deficiencies have been discussed as being able to cause eye lesions (Beach, 1924; Pfister & Renner, 1978; Fujikawa *et al.*, 2003; Crispo *et al.*, 2016; Tang *et al.*, 2020). Although, the likelihood that a grazing bird such as the LWFG, fed a complete pellet showing

symptoms only during certain times of the year would suffer from a vitamin deficiency must be considered low. In some of the studies, deficiencies had to be actively induced (Pfister & Renner, 1978; Fujikawa *et al.*, 2003; Tang *et al.*, 2020) or deficiencies arose in birds raised in a commercial setting (Crispo *et al.*, 2016), further supporting the unlikelihood of the state arising spontaneously in grazing birds on a complete pellet supplemented with both vitamin A and E (Garvo International, n.d.-a; n.d.-b).

5.3 Temperature and rainfall

No effect of rainfall and mean temperature on the number of birds with detected symptoms per day were detected in this study. On the other hand, other authors have shown an increase in eye parasites in birds with increased precipitation and temperature (Blanchard *et al.*, 2018). They did however not link the increased parasite reproduction to an increase in clinical symptoms of infection.

In the current study, a drawback is that the data obtained was not perfect since the weather data from SMHI was only available at certain weather stations. These stations were not located particularly close to Nordens Ark and the data regarding rainfall and temperature had to be obtained from two different weather stations, since data from the investigated time-period was not available in both stations. The dates when the cases were registered are likely not very accurate either. One day a year, month-old goslings are caught for ring marking, and many notes on eye problems are dated to these days because it provides an opportunity to evaluate each gosling up close. However, it is unlikely that all the detected symptoms started on the day of the ring marking. These factors may have influenced the results of the regression model, making the data significantly less precise.

5.4 Drawbacks and improvement potential of the study

Within the frames of this study, it was not possible to investigate the entire population of LWFG ever housed at Nordens Ark due to time restrictions. This could have given a better overview of the situation. To improve the current study, one could however have selected healthy control birds to compare with birds with eye disease, i.e., conducting a case-control study.

One question that was not investigated as a part of this study was whether genetic aspects could influence the occurrence of eye problems. Young birds with eye problems are not sent to reintroduction and they may therefore be saved as breeding individuals to a higher degree. This could lead to an overrepresentation of birds within the breeding population, potentially with a genetically higher likelihood of having eye problems. Ocular abnormalities can be caused by genetic factors,

however, such disorders are mostly described in chickens and some in quails (Shivaprasad *et al.*, 2022). It is also rather unlikely that genetics play an important role in this case since the genetic material of the LWFG at Nordens Ark and Öster Malma is practically the same, while problems seemingly only occurring at Nordens Ark. This topic was not possible to elaborate upon within this study due to time limitations.

Since the question of the importance of water quality has been highlighted, both before, during, and after this study, it would be of great interest to sample the water in the tubs for faecal bacterial load during the summer months at both Öster Malma and Nordens Ark. One could also investigate if changing the type of tubs and provision manner of the water would have any effect on the incidence of eye problems in the population. In conjunction to water sampling, pathogen sampling of eyes in healthy and affected birds could have given indications if the same pathogens are more prevalent in diseased eyes, indicating or dementing a causality between water quality and eye disorders. This was unfortunately not possible due to financial limitations but poses an interesting topic possible to investigate in future studies.

5.5 Conclusion

This study has described and investigated possible causes of eye problems amongst LWFG at Nordens Ark. The manifestations of the disease indicate that it affects the welfare of the birds negatively and poses a risk of, in severe cases, decreasing the number of geese in an already highly threatened species.

No clear evidence of causality between husbandry, certain weather parameters, or clutch size was found in this study. However, a tendency of clutch size having a significant impact on eye problem occurrence was noted. Differences in management and husbandry between Öster Malma and Nordens Ark, such as water supply system, arises questions on the possible impact of water quality on the incidence of eye infections. The literature reviewed on this topic gives no clear answer to the importance of water quality in eye disorders, suggesting further research is needed in the area.

References

- Andersson, Å. (2011). *Åtgärdsprogram för fjällgås 2011-2015*. (6434). Naturvårdsverket.
<https://www.naturvardsverket.se/om-oss/publikationer/6400/atgardsprogram-fjallgas>
[2022-11-02]
- Beach, J.R. (1924). Studies on a nutritional disease of poultry caused by vitamin A deficiency. *University of California Publications*, (378), 24
- Bencina, D., Tadina, T. & Dorrer, D. (1988). Natural infection of ducks with *Mycoplasma synoviae* and *Mycoplasma gallisepticum* and *Mycoplasma* egg transmission. *Avian Pathology*, 17 (2), 441–449.
<https://doi.org/10.1080/03079458808436462>
- BirdLife International (2018). *Lesser White-fronted Goose | Anser erythropus*.
<https://www.iucnredlist.org/species/22679886/132300164> [2022-09-05]
- Blanchard, K.R., Kalyanasundaram, A., Henry, C., Brym, M.Z., Surles, J.G. & Kendall, R.J. (2018). Predicting seasonal infection of eyeworm (*Oxyspirura petrowi*) and caecal worm (*Aulonocephalus pennula*) in northern bobwhite quail (*Colinus virginianus*) of the Rolling Plains Ecoregion of Texas, USA. *International Journal for Parasitology: Parasites and Wildlife*, 8, 50–55.
<https://doi.org/10.1016/j.ijppaw.2018.12.006>
- Blomhoff, R. & Blomhoff, H.K. (2006). Overview of retinoid metabolism and function. *Journal of Neurobiology*, 66 (7), 606–630. <https://doi.org/10.1002/neu.20242>
- Boehringer, E.G., Fornari, O.E. & Boehringer, I.K. (1962). The first case of *Toxoplasma gondii* in domestic ducks in Argentina. *Avian Diseases*, 6 (4), 391–396.
<https://doi.org/10.2307/1587913>
- Brown, J.D., Stallknecht, D.E. & Swayne, D.E. (2008). Experimental Infection of swans and geese with highly pathogenic avian influenza virus (H5N1) of Asian lineage. *Emerging Infectious Diseases*, 14 (1), 136–142.
<https://doi.org/10.3201/eid1401.070740>
- Bruno, A., Fedynich, A.M., Smith-Herron, A. & Rollins, D. (2015). Pathological response of Northern Bobwhites to *Oxyspirura petrowi* infections. *Journal of Parasitology*, 101 (3), 364–368. <https://doi.org/10.1645/14-526.1>
- Buntz, B., Bradbury, J.M., Vuillaume, A. & Rousselot-Paillet, D. (1986). Isolation of *Mycoplasma gallisepticum* from geese. *Avian Pathology*, 15 (3), 615–617.
<https://doi.org/10.1080/03079458608436320>

- Carboneras, C. & Kirwan, G.M. (2020). Lesser white-fronted goose (*Anser erythropus*), version 1.0. *Birds of the World*. <https://doi.org/10.2173/bow.lwfgoo.01>
- Chalmers, W.S. & Kewley, D.R. (1985). Bacterial flora of clinically normal conjunctivae in the domestic duckling. *Avian Pathology: Journal of the W.V.P.A.*, 14 (1), 69–74. <https://doi.org/10.1080/03079458508436208>
- Church, M.L., Barrett, P.M., Swenson, J., Kinsella, J.M. & Tkach, V.V. (2013). Outbreak of *Philophthalmus gralli* in four greater rheas (*Rhea americana*). *Veterinary Ophthalmology*, 16 (1), 65–72. <https://doi.org/10.1111/j.1463-5224.2012.01008.x>
- Crispin, S.M. & Barnett, K.C. (1978). Ocular candidiasis in ornamental ducks. *Avian Pathology*, 7 (1), 49–59. <https://doi.org/10.1080/03079457808418259>
- Crispo, M., Palmieri, C. & Shivaprasad, H. (2016). Myopathy of the pipping muscles, hepatitis dietetica, and cataracts in emu chicks (*Dromaius novaehollandiae*). *Veterinary Pathology*, 53. <https://doi.org/10.1177/0300985816638720>
- Dickx, V., Kalmar, I.D., Tavernier, P. & Vanrompay, D. (2013). Prevalence and genotype distribution of *Chlamydia psittaci* in feral Canada geese (*Branta canadensis*) in Belgium. *Vector-Borne and Zoonotic Diseases*, 13 (6), 382–384. <https://doi.org/10.1089/vbz.2012.1131>
- Dubey, J.P., Garner, M.W., Willette, M.M., Batey, K.L. & Gardiner, C.H. (2001). Disseminated toxoplasmosis in magpie geese (*Anseranas semipalmata*) with large numbers of tissue cysts in livers. *Journal of Parasitology*, 87 (1), 219–223. [https://doi.org/10.1645/0022-3395\(2001\)087\[0219:DTIMGA\]2.0.CO;2](https://doi.org/10.1645/0022-3395(2001)087[0219:DTIMGA]2.0.CO;2)
- Egyed, M.N., Shlosberg, A., Eilat, A., Malkinson, M. & Barishak, Y.R. (1975). Chronic lesions in geese photosensitized by *Ammi majus*. *Avian Diseases*, 19 (4), 822–826. <https://doi.org/10.2307/1589196>
- European Committee on Legal Co-Operation (1999). *Recommendation concerning domestic geese*. <https://www.coe.int/en/web/cdcj/1999-rec-domestic-geese> [2022-11-05]
- Ferenczi, M., Beckmann, C., Warner, S., Loyn, R., O’Riley, K., Wang, X. & Klaassen, M. (2016). Avian influenza infection dynamics under variable climatic conditions, viral prevalence is rainfall driven in waterfowl from temperate, south-east Australia. *Veterinary Research*, 47 (1), 23. <https://doi.org/10.1186/s13567-016-0308-2>
- Frederick, R.B. & Klaas, E.E. (1982). Resource use and behavior of migrating snow geese. *The Journal of Wildlife Management*, 46 (3), 601–614. <https://doi.org/10.2307/3808550>
- Fujikawa, A., Gong, H. & Amemiya, T. (2003). Vitamin E prevents changes in the cornea and conjunctiva due to vitamin A deficiency. *Graefe’s Archive for Clinical and Experimental Ophthalmology*, 241 (4), 287–297. <https://doi.org/10.1007/s00417-003-0633-9>

- Garvo International (n.d.-a). *816 waterfowl condition/show pellet*.
<https://www.garvo.nl/en/assortment/816-waterfowl-condition-show-pellet/> [2022-12-07]
- Garvo International (n.d.-b). *803 waterfowl breeder pellet*.
<https://www.garvo.nl/en/assortment/803-waterfowl-breeder-pellet/> [2022-12-07]
- Gleeson, M.D., Moore, B.A., Edwards, S.G., Stevens, S., Childress, A.L., Wellehan, J.F.X., Robertson, J., Murphy, C.J., Hawkins, M.G. & Paul-Murphy, J. (2019). A novel herpesvirus associated with chronic superficial keratitis and proliferative conjunctivitis in a great horned owl (*Bubo virginianus*). *Veterinary Ophthalmology*, 22 (1), 67–75. <https://doi.org/10.1111/vop.12570>
- Griggs, A. (2019). Ocular surface disease in birds. *Veterinary Clinics of North America: Exotic Animal Practice*, 22 (1), 53–68. <https://doi.org/10.1016/j.cvex.2018.08.005>
- Hacking, M.A. & Sileo, L. (1977). Isolation of a hemolytic *Actinobacillus* from waterfowl. *Journal of wildlife diseases*, 13 (1), 69–73. <https://doi.org/10.7589/0090-3558-13.1.69>
- Hansen, W. (1999). *Avian pox*. (Information and Technology Report, 1999–0001). Reston, VA: U.S. Geological Survey. <http://pubs.er.usgs.gov/publication/2001161> [2022-11-06]
- Holmberg, B.J. (2008). Chapter 20 - Ophthalmology of Exotic Pets. In: Maggs, D.J., Miller, P.E., & Ofri, R. (eds) *Slatter's Fundamentals of Veterinary Ophthalmology*. 4th ed., Saint Louis: W.B. Saunders. 427–441. <https://doi.org/10.1016/B978-072160561-6.50023-X>
- Jiang, D., Liu, L., Wang, C., Chen, F., Sun, A. & Shi, Z. (2011). Raising on water stocking density reduces geese reproductive performances via water bacteria and lipopolysaccharide contaminations in “geese-fish” production system. *Agricultural Sciences in China*, 10 (9), 1459–1466. [https://doi.org/10.1016/S1671-2927\(11\)60139-9](https://doi.org/10.1016/S1671-2927(11)60139-9)
- Jones, T., Martin, K., Barov, B. & Nagy, S. (2008). *International Single Species Action Plan for the Conservation of the Western Palearctic Population of the Lesser White-fronted Goose Anser erythropus*. (AEWA Technical Series No.36.). Bonn, Germany: Agreement on the Conservation of African-Eurasian Migratory Waterbirds. <https://www.unep-aewa.org/en/publication/international-single-species-action-plan-conservation-lesser-white-fronted-geese-western> [2022-11-10]
- Jones, T.A., Waite, C.D. & Dawkins, M.S. (2009). Water off a duck's back: Showers and troughs match ponds for improving duck welfare. *Applied Animal Behaviour Science*, 116 (1), 52–57. <https://doi.org/10.1016/j.applanim.2008.07.008>
- Kirmse, P. (1967). Experimental pox infection in waterfowl. *Avian Diseases*, 11 (2), 209–216. <https://doi.org/10.2307/1588115>
- Liao, S.-C., Lu, P.-X., Shen, S.-Y., Hsiao, C.-C., Lien, C.-Y., Wang, S.-D., Lin, T.-Y. & Tu, P.-A. (2021). Effects of different swimming pool conditions and floor types on

- growth performance and footpad dermatitis in indoor-reared White Roman geese. *Animals*, 11 (6), 1705. <https://doi.org/10.3390/ani11061705>
- Lipphaus, P., Hammes, F., Köttsch, S., Green, J., Gillespie, S. & Nocker, A. (2014). Microbiological tap water profile of a medium-sized building and effect of water stagnation. *Environmental Technology*, 35 (5), 620–628. <https://doi.org/10.1080/09593330.2013.839748>
- Liste, G., Kirkden, R.D. & Broom, D.M. (2012). A commercial trial evaluating three open water sources for farmed ducks: effects on health and production. *British Poultry Science*, 53 (5), 576–584. <https://doi.org/10.1080/00071668.2012.736613>
- Liste, G., Kirkden, R.D. & Broom, D.M. (2013). A commercial trial evaluating three open water sources for farmed ducks: effects on water usage and water quality. *British Poultry Science*, 54 (1), 24–32. <https://doi.org/10.1080/00071668.2013.763900>
- Maddux, R.L., Chengappa, M.M. & McLaughlin, B.G. (1987). Isolation of *Actinobacillus suis* from a Canada goose (*Branta canadensis*). *Journal of Wildlife Diseases*, 23 (3), 483–484. <https://doi.org/10.7589/0090-3558-23.3.483>
- Madsen, J. (1996). *International Action Plan for the Lesser White-Fronted Goose (Anser erythropus)*. National Environmental Research Institute of Denmark.
- Marusich, W.L., Ogrinz, E.F., Brand, M. & Mitrovic, M. (1970). Induction, prevention and therapy of biotin deficiency in turkey poult on semi-purified and commercial-type rations. *Poultry Science*, 49 (2), 412–421. <https://doi.org/10.3382/ps.0490412>
- Mashaly, M.M., Hendricks, G.L., Kalama, M.A., Gehad, A.E., Abbas, A.O. & Patterson, P.H. (2004). Effect of heat stress on production parameters and immune responses of commercial laying hens. *Poultry Science*, 83 (6), 889–894. <https://doi.org/10.1093/ps/83.6.889>
- Mason, R.W. (1986). Conjunctival cryptosporidiosis in a duck. *Avian Diseases*, 30 (3), 598–600. <https://doi.org/10.2307/1590428>
- Mellor, D. & Reid, C.S.W. (1994). Concepts of animal well-being and predicting the impact of procedures on experimental animals. *Experimental Research and Animal Welfare Collection*. <https://www.wellbeingintlstudiesrepository.org/exprawel/7>
- Moore, B.A., Fernandez-Juricic, E., Hawkins, M.G., Montiani-Ferreira, F. & Ribas Lange, R. (2022). Introduction to ophthalmology of aves. In: *Wild and Exotic Animal Ophthalmology: Volume 1: Invertebrates, Fishes, Amphibians, Reptiles, and Birds*. Cham: Springer International Publishing AG. 321–348.
- Murata, K. & Asakawa, M. (1999). First report of *Thelazia* sp. from a captive oriental white stork (*Ciconia boyciana*) in Japan. *Journal of Veterinary Medical Science*, 61 (1), 93–95. <https://doi.org/10.1292/jvms.61.93>
- Nordens Ark (n.d.). *Lesser White-Fronted Goose*. <https://en.nordensark.se/conservation/conservation-sweden/lesser-white-fronted-goose/> [2022-10-07]

- O'Driscoll, K.K.M. & Broom, D.M. (2011). Does access to open water affect the health of Pekin ducks (*Anas platyrhynchos*)? *Poultry Science*, 90 (2), 299–307.
<https://doi.org/10.3382/ps.2010-00883>
- Øien, I. & Aarvak, T. (2006). *Monitoring of Lesser White fronted Goose in Norway in 2005*. (NOF report 4-2005). Norsk Ornitologisk Forening.
- Onozuka, D., Hashizume, M. & Hagihara, A. (2009). Impact of weather factors on *Mycoplasma pneumoniae* pneumonia. *Thorax*, 64 (6), 507–511.
<https://doi.org/10.1136/thx.2008.111237>
- Pantin-Jackwood, M.J., Suarez, D.L., Spackman, E. & Swayne, D.E. (2007). Age at infection affects the pathogenicity of Asian highly pathogenic avian influenza H5N1 viruses in ducks. *Virus Research*, 130 (1), 151–161.
<https://doi.org/10.1016/j.virusres.2007.06.006>
- Parenti, E., Sola, S.C., Turilli, C. & Corazzola, S. (1986). Spontaneous toxoplasmosis in canaries (*Serinus canaria*) and other small passerine cage birds. *Avian Pathology*, 15 (2), 183–197. <https://doi.org/10.1080/03079458608436280>
- Pfister, R.R. & Renner, M.E. (1978). The corneal and conjunctival surface in vitamin A deficiency: a scanning electron microscopy study. *Investigative Ophthalmology & Visual Science*, 17 (9), 874–883
- Phillips, B.E., Dierenfeld, E.S., English, R., Troan, B., Reininger, K., Zombeck, D.J., DeVoe, R.S., Wolfe, B., Loomis, M.R. & Minter, L.J. (2022). Retrospective analysis of cataract formation and nutritional etiology in a managed collection of parakeet auklets (*Aethia psittacula*). *Journal of Avian Medicine and Surgery*, 35 (4), 390–401.
<https://doi.org/10.1647/20-00037>
- Pocknell, A.M., Miller, B.J., Neufeld, J.L. & Grahn, B.H. (1996). Conjunctival mycobacteriosis in two emus (*Dromaius novaehollandiae*). *Veterinary Pathology*, 33 (3), 346–348. <https://doi.org/10.1177/030098589603300314>
- Raidal, S.R. (1995). Staphylococcal dermatitis in quail with a parakeratotic hyperkeratotic dermatosis suggestive of pantothenic acid deficiency. *Avian Pathology*, 24 (3), 579–583. <https://doi.org/10.1080/03079459508419097>
- Rodenburg, B., Bracke, M.B.M., Berk, J., Cooper, J., FAURE, J.M., Guémené, D., Harlander, A., Jones, T., Knierim, U., Kuhnt, K., Pingel, H., Reiter, K., Serviere, J. & Ruis, M.A.W. (2005). Welfare of ducks in European duck husbandry systems. *Worlds Poultry Science Journal* 61 (2005) 4, 61. <https://doi.org/10.1079/WPS200575>
- Rostami, A., Madani, S.A. & Vajhi, A. (2011). Necrotic dermatitis in waterfowl associated with consumption of perennial rye grass (*Lolium perenne*). *Journal of Avian Medicine and Surgery*, 25 (1), 44–49. <https://doi.org/10.1647/2009-051.1>
- Sadar, M.J., Guzman, D.S.-M., Burton, A.G., Byrne, B.A., Wiggans, K.T. & Hollingsworth, S.R. (2014). Mycotic keratitis in a khaki Campbell duck (*Anas platyrhynchos domesticus*). *Journal of Avian Medicine and Surgery*, 28 (4), 322–329.
<https://doi.org/10.1647/2013-050>

- Schenk, A., Porter, A.L., Alenciks, E., Frazier, K., Best, A.A., Fraley, S.M. & Fraley, G.S. (2016). Increased water contamination and grow-out Pekin duck mortality when raised with water troughs compared to pin-metered water lines using a United States management system. *Poultry Science*, 95 (4), 736–748.
<https://doi.org/10.3382/ps/pev381>
- Shivaprasad, H.L., Montiani-Ferreira, F. & Moore, B.A. (2022). Ophthalmology of Galloanserae: Fowl, Waterfowl, & Relatives. In: *Wild and Exotic Animal Ophthalmology: Volume 1: Invertebrates, Fishes, Amphibians, Reptiles, and Birds*. Cham: Springer International Publishing AG. 571–626.
- Shlosberg, A. & Egyed, M.N. (1978). Photosensitization in ducklings induced by seeds of *Cymopterus watsonii* and *C. longipes*. *Avian Diseases*, 22 (4), 576–582.
<https://doi.org/10.2307/1589632>
- SLU Artdatabanken (2020). *Rödlistade arter i Sverige 2020*. SLU, Uppsala: SLU Artdatabanken. <https://www.artdatabanken.se/publikationer/bestall-publikationer/bestall-rodlista-2020/> [2022-11-02]
- SLU Artdatabanken (n.d.-a). *Engelskt rajgräs / Lolium perenne*.
<https://artfakta.se/artbestamning/taxon/lolium%20perenne-222561?src=2&class=128> [2022-10-18]
- SLU Artdatabanken (n.d.-b). *Slöjssilja / Ammi majus*.
<https://artfakta.se/artbestamning/taxon/ammi-majus-221600> [2022-10-18]
- SLU Artdatabanken (n.d.-c). *Thelazia lacrymalis*.
<https://artfakta.se/artbestamning/taxon/thelazia-lacrymalis-248268> [2023-01-11]
- SMHI (n.d.-a.). *Ladda ner meteorologiska observationer - Väderöarna A*.
<https://www.smhi.se/data/meteorologi/ladda-ner-meteorologiska-observationer#param=airtemperatureInstant,stations=core,stationid=81350> [2022-11-08]
- SMHI (n.d.-b). *Ladda ner meteorologiska observationer - Heden*.
<https://www.smhi.se/data/meteorologi/ladda-ner-meteorologiska-observationer#param=precipitation24HourSum,stations=core,stationid=81310> [2022-11-08]
- Star, L., Nieuwland, M.G.B., Kemp, B. & Parmentier, H.K. (2007). Effect of single or combined climatic and hygienic stress on natural and specific humoral immune competence in four layer lines. *Poultry Science*, 86 (9), 1894–1903.
<https://doi.org/10.1093/ps/86.9.1894>
- Statens Veterinärmedicinska Anstalt (2022a). *Kryptosporidiosis hos kalv*.
<https://www.sva.se/amnesomraden/djursjukdomar-a-o/kryptosporidiosis-hos-kalv/> [2023-01-11]
- Statens Veterinärmedicinska Anstalt (2022b). *Toxoplasmos hos vilda djur*.
<https://www.sva.se/amnesomraden/djursjukdomar-a-o/toxoplasmos-hos-vilda-djur/> [2023-01-11]

- Surman, P.G., Schultz, D.J. & Tham, V.L. (1974). Keratoconjunctivitis and chlamydiosis in cage birds. *Australian Veterinary Journal*, 50 (8), 356–362.
<https://doi.org/10.1111/j.1751-0813.1974.tb14106.x>
- Svenska Jägareförbundet (n.d.). *Projekt Fjällgås*. <https://jagareforbundet.se/Projekt-fjallgas/> [2022-10-24]
- Tang, J., Zhang, B., Xue, M., Shi, W.B., Wu, Y.B., Feng, Y.L., Huang, W., Zhou, Z.K., Xie, M. & Hou, S.S. (2020). Pantothenic acid requirement of male White Pekin ducks from hatch to 21 days of age. *Animal Feed Science and Technology*, 269, 114637.
<https://doi.org/10.1016/j.anifeedsci.2020.114637>
- United States Department of Agriculture | Natural Resources Conservation Service (n.d.). *Cymopterus Raf. / springparsley*.
<https://plants.usda.gov/home/plantProfile?symbol=CYMOP2> [2022-10-18]
- Vellayan, S., Jeffery, J., Oothuman, P., Zahedi, M., Krishnasamy, M., Paramaswaran, S., Rohela, M. & Abdul-Aziz, N.M. (2012). Oxyspiruriasis in zoo birds. *Tropical Biomedicine*, 29 (2), 304–307
- Vermeulen, L.C. & Hofstra, N. (2014). Influence of climate variables on the concentration of *Escherichia coli* in the Rhine, Meuse, and Drentse Aa during 1985–2010. *Regional Environmental Change*, 14 (1), 307–319.
<https://doi.org/10.1007/s10113-013-0492-9>
- Wan, H., Chen, L., Wu, L. & Liu, X. (2004). Newcastle disease in geese: natural occurrence and experimental infection. *Avian Pathology*, 33 (2), 216–221.
<https://doi.org/10.1080/0307945042000195803>
- Wiedermann, U., Chen, X.-J., Enerbäck, L., Hanson, L.Å., Kahu, H. & Dahlgren, U.I. (1996a). Vitamin a deficiency increases inflammatory responses. *Scandinavian Journal of Immunology*, 44 (6), 578–584. <https://doi.org/10.1046/j.1365-3083.1996.d01-351.x>
- Wiedermann, U., Tarkowski, A., Bremell, T., Hanson, L.A., Kahu, H. & Dahlgren, U.I. (1996b). Vitamin A deficiency predisposes to *Staphylococcus aureus* infection. *Infection and Immunity*, 64 (1), 209–214. <https://doi.org/10.1128/iai.64.1.209-214.1996>
- Williams, D.L. (2012). Chapter 9 - The avian eye. In: *Ophthalmology of Exotic Pets*. Hoboken, United Kingdom: John Wiley & Sons, Incorporated.
<http://ebookcentral.proquest.com/lib/slub-ebooks/detail.action?docID=894835> [2022-10-27]
- Williams, S.M., Fulton, R.M., Render, J.A., Mansfield, L. & Bouldin, M. (2001). Ocular and encephalic toxoplasmosis in canaries. *Avian Diseases*, 45 (1), 262–267.
<https://doi.org/10.2307/1593039>
- Zamora-Vilchis, I., Williams, S.E. & Johnson, C.N. (2012). Environmental temperature affects prevalence of blood parasites of birds on an elevation gradient: Implications

for disease in a warming climate. *PLoS ONE*, 7 (6), e39208.
<https://doi.org/10.1371/journal.pone.0039208>

Popular Science Summary

Eye problems are common amongst captive birds and become especially problematic in endangered species, such as the lesser white-fronted goose. This is the case at Nordens Ark where reoccurring eye problems are seen amongst their population of this goose species. Nordens Ark is a part of a conservation project breeding geese to reintroduce young goslings into the wild. This study aimed to describe the eye problems seen within this population and investigate their possible causes. At the breeding facility of the Swedish Association of Hunting and Wildlife Management in Öster Malma Wildlife Park, collaborating closely with Nordens Ark and housing birds within the same genetic background, no eye problems have been detected. Both facilities were visited to determine differences in the management of the birds that could explain why eye problems are only seen at Nordens Ark. As a part of this keeper interviews were conducted. Medical records and general information from lesser white-fronted geese at Nordens Ark with eye problems between 2009 and 2021 were obtained to give an overview of the problems seen and characterize which birds are affected. Impacts of weather parameters (rainfall and temperature) on number of eye disease cases were also investigated, as well as the implication of clutch size on the likelihood of a bird obtaining eye problems.

The most common symptoms of eye disease seen were signs of eye pain, involvement of the eye surface, inflammation in the mucous membrane surrounding the eye, and feather loss around the eye. Painful eye problems may negatively impact the welfare of the birds, which is why it is important to determine the underlying cause to mitigate the problem. Eye diseases were almost exclusively observed between May and September and birds under two months were the most affected age group, followed by birds older than two years of age. No impact from rainfall or temperature on the number of birds with symptoms from the eyes was found. Regarding management differences between Nordens Ark and Öster Malma, water provision was the greatest difference, with Nordens Ark using manually maintained plastic tubs and Öster Malma using concrete pools with constant refill and outflow of water. One hypothesis is that water quality at Nordens Ark is negatively impacted during the summer months, due to the facts that higher temperatures may cause increased growth of bacteria in the water and there are more birds soiling the water during this time since the adults also must share the

tubs with the goslings. A higher number of bacteria in the water may increase the risk of birds acquiring eye infections. A tendency of scientific proof of clutch size impacting the risk of a bird having eye problems was seen, which can also support this theory.

It is important to find significant evidence of the cause, or causes, of the eye problems seen amongst the lesser white-fronted geese at Nordens Ark to have a chance to prevent them. This is important both to mitigate negative consequences for the individual birds in the form of e.g., eye pain but also to ensure as many of the birds as possible survive and thrive for them to contribute to the survival of the species. Further studies on the matter are needed to provide such evidence.

Acknowledgements

A warm thank you to John at Nordens Ark and Sarah at Öster Malma Wildlife Park for taking the time out of your days to give tours on the respective premises and provide elaborate descriptions of the husbandry of the lesser white-fronted geese in your care. Thank you to Michelle and Elin at the veterinary department at Nordens Ark for providing pictures of geese with eye problems, answering questions, and sharing a very valuable summary of the medical information on the geese with eye problems. I would also like to thank my supervisor Jenny for invaluable feedback, discussions, and support along the way. Finally, a special thank you to my boyfriend Johan for never hesitating to discuss goose matters at the dining table.

Publishing and archiving

Approved students' theses at SLU are published electronically. As a student, you have the copyright to your own work and need to approve the electronic publishing. If you check the box for **YES**, the full text (pdf file) and metadata will be visible and searchable online. If you check the box for **NO**, only the metadata and the abstract will be visible and searchable online. Nevertheless, when the document is uploaded it will still be archived as a digital file. If you are more than one author, the checked box will be applied to all authors. Read about SLU's publishing agreement here:

- <https://www.slu.se/en/subweb/library/publish-and-analyse/register-and-publish/agreement-for-publishing/>.

☒ YES, I hereby give permission to publish the present thesis in accordance with the SLU agreement regarding the transfer of the right to publish a work.

☐ NO, I do not give permission to publish the present work. The work will still be archived and its metadata and abstract will be visible and searchable.