



Sveriges lantbruksuniversitet
Fakulteten för veterinärmedicin och husdjursvetenskap

Injuries to the suspensory ligament – etiology, prevalence and prevention

Maja Wiklund



Självständigt arbete i veterinärmedicin, 15 hp

Veterinärprogrammet, examensarbete för kandidatexamen Nr. 2011:64

Institutionen för biomedicin och veterinär folkhälsovetenskap

Uppsala 2011



Sveriges lantbruksuniversitet
Fakulteten för veterinärmedicin och husdjursvetenskap

Injuries to the suspensory ligament – etiology, prevalence and prevention

Gaffelbandsskador på häst – etiologi, prevalens och förebyggande åtgärder

Maja Wiklund

Handledare:

Fredrik Södersten, SLU, Institutionen för biomedicin och veterinär folkhälsovetenskap

Examinator:

Mona Fredriksson, SLU, Institutionen för biomedicin och veterinär folkhälsovetenskap

Omfattning: 15 hp

Kurstitel: Självständigt arbete i veterinärmedicin

Kurskod: EX0700

Program: Veterinärprogrammet

Nivå: Grund, G2E

Utgivningsort: SLU Uppsala

Utgivningsår: 2011

Omslagsbild: Maja Wiklund

Serienamn, delnr: Veterinärprogrammet, examensarbete för kandidatexamen Nr. 2011:64
Institutionen för biomedicin och veterinär folkhälsovetenskap, SLU

On-line publicering: <http://epsilon.slu.se>

Nyckelord: Gaffelband, häst, anatomi, skada, prevalens, etiologi, förebygga

Key words: Suspensory ligament, horse, anatomy, injury, prevalence, etiology, prevention

TABLE OF CONTENTS

| | |
|---|----|
| Sammanfattning | 1 |
| Summary | 2 |
| Introduction | 3 |
| Metods | 3 |
| Literature review | 4 |
| Anatomy | 4 |
| Histology..... | 4 |
| Injuries..... | 5 |
| Desmitis | 5 |
| Degeneration..... | 6 |
| Suspensory breakdown | 6 |
| Avulsion fracture | 7 |
| Prevalence of injuries in the suspensory ligament | 7 |
| Exercise and training | 8 |
| Discussion | 9 |
| References | 11 |

SAMMANFATTNING

Gaffelbandet är som ett ligament men innehåller även muskelfibrer som ligger i buntar. Inflammation är den vanligaste skadan i gaffelbandet. Den kan vara lokaliserad till den proximala delen, till mittendelen av gaffelbandet eller till grenarna. Inflammationen kan ge upphov till olika grad av svullnad, värme, smärta vid palpation och hälta. Det finns även en ärftlig skada, en degeneration av gaffelbandet, som förekommer främst hos hästar av rasen Peruvian Paso. Olika studier har undersökt prevalensen på gaffelbandsskador, sammanfattningsvis kan man säga att det drabbar alla typer av hästar, oavsett sport och ras, men framförallt är det ett problem hos dressyrhästar. Orsaken till detta kan bero på de rörelser dessa hästar utför och också på att unghästar som har väldigt bra gång har en större risk att få inflammation i gaffelbandet.

För att komma till rätta med detta problem är det viktigt att man tränar och håller hästen på ett sätt som gör att gaffelbandet inte utsätts för större belastning än vad det är moget för.

SUMMARY

The suspensory ligament is like a normal ligament with the difference that it also has bundles of muscle fibers. Desmitis in the suspensory ligament is the most common injury and it can affect the proximal part, the body or the branches. The desmitis can give different severeness of swelling, heat, pain on palpation and lameness. There is also an inheritable disease, degenerative suspensory ligament desmitis, which is most common in horses of the breed Peruvian Paso. Different studies have researched the prevalence on injuries to the suspensory ligament. To sum up it can affect all types of horses but is particularly a problem in dressage horses. The reason for this might be the movements that these horses perform and also that the young horses with extremely good gait have a higher risk to get desmitis.

The most important thing to get on top of this problem is probably to train and keep the horse in a way so that the suspensory ligament does not get exposed to a higher strain than it is matured for.

INTRODUCTION

Injuries to the suspensory ligament can affect all types of horses in any type of sport and at all different levels of competition. The suspensory ligament is in some aspects a single unit but in other aspects, like the histological, the different parts of the ligament are heterogeneous. This reflects in the numerous injuries and diseases in the suspensory ligament, of which some will be described in this text. Dressage horses seem to be the group with the highest risk to get lame or not perform at their top level because of suspensory ligament damage. The aim of this study is to see what type of horses get injuries in the suspensory ligament and what are the characteristics of these injuries. Is there a difference between breeds and different types of injuries or are injuries more connected to what type of sport the horse competes in?

This essay will try to answer questions about the reason for this. Is it inheritable, is it because of the different training methods or might it be because of the way the horse is held during its upbringing?

METHODS

A search was made on “interosseus muscle” AND (equine OR horse*) in Web of Knowledge and the result in that database was 12. The same search was made in Pub Med and the result there was 4. When a search for “suspensory ligament” AND (equine OR horse*) was made in Web of Knowledge the result was 258 and in Pub Med the result was 114. Selection was based on relevance after reading titles and abstracts. Furthermore, searches for relevant references in the found articles were made.

LITERATURE REVIEW

Anatomy

The suspensory ligament is not like a normal ligament, it has been developed from the interosseus muscle. The suspensory ligament has three parts, the proximal, the body and the branches. The proximal part originates from the proximal third metacarpal or metatarsal bone on the caudal surface (Soffler & Hermanson, 2006). The body goes down between the second and fourth metacarpal or metatarsal bone before it divides in to two branches. The branches attach to sesamoid bones in the fetlock joint (Figure 1). The suspensory ligament provides support in the fetlock joint and prevents over-extension (Davidson, 2009).

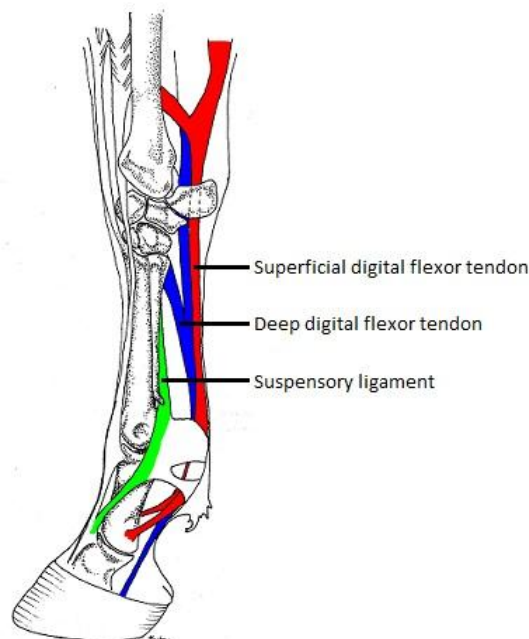


Figure 1. The suspensory ligament in relation to the superficial and the deep digital flexor tendons. Illustrated by Karolina Larsson.

Histology

The suspensory ligament looks like a ligament from the outside but about 10% of the ligament consists of muscle fibers. Most of the fibers are type I and occur mostly below the surface and are arranged in loose bundles. Type I muscle fibers have a slow contraction time and a high resistance to fatigue. There are some type II muscle fibers as well, about 5% of all the muscle fibers, distributed throughout the suspensory ligament (Soffler & Hermanson, 2006). The type II fibers have a faster contraction time, but are less resistant to fatigue compared to the type I muscle fibers. The muscle fibers are surrounded by connective tissue. In the proximal part there are dense collagen bundles, with loose fibrous tissue containing blood vessels, surrounding the bundles. The body part of the ligament looks similar to the proximal part, but it contains more muscle fibers. In the proximal part of the branches the collagen bundles are well-organized and arranged in one direction. These bundles are

separated by thick fibrous septa. The distal part of the branches has short and less organized collagen fibers (Souza *et al.*, 2010).

There is some heterogeneity in the suspensory ligament. In the proximal part and in the body there is some adipose tissue and muscle bundles and the branches look more like real tendons (Souza *et al.*, 2010). This might be because the body of the ligament was originally a muscle and the branches were the tendon that it was attached to. This can be seen in horse fetuses, where there is no adipose tissue and the outlines consist of muscle fibers (Cunningham, 1883). The body is also much stiffer than the other parts of the suspensory ligament and it does not have the same arrangement of the collagen fibers that the proximal part and the branches have (Souza *et al.*, 2010). The amount of muscle tissue is to a certain point individual but it can vary quite a bit between breeds (Gibson & Steel, 2002). For example Standardbreds have around 40% more muscle tissue than Thoroughbreds in their suspensory ligament (Wilson *et al.*, 1991). Standardbreds also have more muscle tissue in the suspensory ligament in the forelimb than in the one in the hindlimb, in Thoroughbreds it is the opposite, the suspensory ligament in the hindlimb contains more muscle tissue than the same ligament in the forelimb (Soffler & Hermanson, 2006).

The biochemical composition is more or less similar in all parts of the suspensory ligament. This is probably because the anatomical configuration gives it only tensile load. In this respect you can see the suspensory ligament as a single functional unit (Souza *et al.*, 2010).

Injuries

There are several ways in which the horse can injure its suspensory ligament: proximal suspensory desmitis, desmitis of the body, desmitis of the branches, degeneration, suspensory breakdown injuries and avulsion of the origin of the suspensory ligament (Gibson & Steel, 2002).

Desmitis

Desmitis is an inflammation in a ligament. If the suspensory ligament is injured, collagen fibrils are stretched and torn. The pain on palpation, heat and swelling occur because of this and because of hematomas that appears when the small blood vessels in the ligament are damaged as well. Right after the injury the healing process begins. Damaged tissue is removed by phagocytes and new collagen is produced. A higher proportion of type III fibrils and not the original type I is formed. The type III fibrils have a smaller diameter and are not arranged in an organized way. Over time the collagen will rearrange and increase its diameter so it will look more like before the injury. The new tissue is however not as strong and elastic and the risk of re-injury is high. If the injury is more of a chronic strain the result is more fibrous tissue and in the end an enlarged ligament (Gibson & Steel, 2002).

Proximal suspensory desmitis occurs in all types of horses and in all classes. If the horse has a straight hock or a hyperextension in the fetlock it is at a greater risk of injury (Dyson, 2007). The desmitis is located in the proximal third of the metacarpal or metatarsal bone. Proximal suspensory desmitis causes lameness that is moderate to mild and it can be either chronic or

acute (Gibson & Steel, 2002). The lameness can disappear after a few days of rest if it is located in the forelimb but it will return when the horse is put back into training. If the proximal suspensory desmitis has affected the hindlimb the lameness is more persistent (Stashak, 2001).

Desmitis of the body of the suspensory ligament can affect all horses and is more common in the forelimb in all breeds but Standardbreds where it occurs in both the forelimb and in the hindlimb (Stashak, 2001). The desmitis can be located to just the body of the ligament but it is common that one or both branches are affected as well. Lameness caused by desmitis of the body is variable and is often mild. Instead there is swelling and pain on palpation (Gibson & Steel, 2002).

Desmitis of the branches of the suspensory ligament affects both forelimb and hindlimb in all types of horses (Stashak, 2001). There is a theory that foot imbalance is a predisposing factor (Dyson, 2007). The inflammation gives swelling of one or both branches and pain on palpation. The lesion causes lameness that may vary a lot in degree and might even be absent (Gibson & Steel, 2002).

Degeneration

Degenerative suspensory ligament desmitis is inheritable and primarily affects Peruvian Pasos and Peruvian Paso crosses. It is a chronic disease that gives a slowly progressing lameness which can be bilateral or quadrilateral (Halper *et al.*, 2011). The degeneration and elongation of the suspensory ligament gives a hyperextension of the fetlock joint (Gibson & Steel, 2002).

New research showed that this probably is not a disease that only is located to the suspensory ligament but rather a systemic disorder (Halper *et al.*, 2006). The disorder causes proteoglycan accumulation in tissues and organs that have a high content of connective tissue. For example they showed in their study that all the horses with degenerative suspensory ligament desmitis, also had affected superficial and deep digital flexor tendons. Furthermore, increased levels of proteoglycan were found in the aorta, in the pulmonary arteries, in the coronary arteries and in the sclera (the white of the eye). It has therefore been suggested that degenerative suspensory ligament desmitis should change name to equine systemic proteoglycan accumulation (Halper *et al.*, 2006).

Schenkman *et al.* (2009) did a comparison of horses affected with degenerative suspensory ligament desmitis and horses that were not affected. They studied proteoglycan accumulation in ligament and tendon in the limbs, aorta, heart, eye, brain and visceral organs. The result was that there was no difference in proteoglycan accumulation between the affected and unaffected horses in all places except the suspensory ligament and the distal flexor tendons. And their conclusion was that it is not a systemic disease.

Suspensory breakdown

Suspensory breakdown injury is most common in Thoroughbred racehorses. The breakdown can occur in the body, in the branches, in the sesamoid bones or in the ligament that descends

from these bones. All support to the fetlock fails and the horse is unable to put weight on the affected limb, if weight is put on the limb it will lead to a grave hyperextension in the joint (Gibson & Steel, 2002).

Avulsion fracture

Avulsion of the origin of the suspensory ligament can happen to both the forelimb and the hindlimb, but mostly affects performance horses' forelimbs in training. What occurs is that a piece of bone is pulled away with the suspensory ligament from the third metacarpal or metatarsal bone and it gives an acute, severe lameness (Gibson & Steel, 2002). According to Rooney (1986) the mechanism behind avulsion fracture is an incorrect position in the fetlock joint in relation to the carpus when the hoof hits the ground. The carpus is still in the palmar flexed position when the fetlock joint is dorsiflexing, which causes a larger strain. Because of the palmar flexion in the carpus only the third metacarpal bone will be affected, in other words it is the suspensory ligament that will be stretched beyond its limit. It is not sure that there will be any pain on palpation, heat or swelling but it occurs most of the time. The lameness is more evident when the horse is trotting in a circle (Gibson & Steel, 2002).

Prevalence of injuries in the suspensory ligament

There has been a lot of research on what type of injury horses get in the suspensory ligament and also if there is an association between type of sport and type of injuries. According to Dyson (2002), proximal suspensory desmitis and injuries to the branches of the suspensory ligament are the most common reasons to why a dressage horse cannot perform at their maximum level. For show jumping horses proximal suspensory desmitis in the forelimb and desmitis of the branches in both the forelimb and hindlimb are among the most frequent injuries. Proximal suspensory desmitis and injuries to the suspensory branches are often the cause for acute lameness in the event horse (Dyson, 2002).

Kasashima *et al.* (2004) looked at over 10 000 Thoroughbred racehorses in Japan and the prevalence of suspensory ligament desmitis under the year of 1999. They only included flat racehorses since the national hunt racehorses have different training and age variety. The result was that 370 horses (3.61%) got desmitis in the forelimb and 14 horses (0.14%) got desmitis in the hindlimb. In the group that got desmitis in the forelimb they found that there was an increased risk the older the horse got. They could also see that males had a much higher risk to get desmitis in the suspensory ligament than females and geldings. They compared these results with the prevalence of superficial digital flexor tendonitis. The prevalence of superficial digital flexor tendonitis was higher in total and like suspensory ligament desmitis the risk was higher for males. The risk also increased with age but not in the same degree as for suspensory ligament desmitis.

Dyson *et al.* (2006) looked at what influence performance level and type of sport had on the risk of orthopedic injury and where it was located. They took records from The Animal Health Trust (January 1998-October 2003) and looked at the horses that had got orthopaedic evaluation but excluded the ones that did not get a diagnosis or did not have a defined work discipline; in total they got 1069 cases. The horses were divided in to thirteen different work

disciplines and also divided after level of competition. The results showed that injuries to the suspensory ligament are the most common injuries for general purpose, elite show jumping, elite dressage and non-elite dressage horses. In the dressage horses, both elite and non-elite the injury was mostly located to the hindlimb. 28.1% of the injuries to the elite dressage horses were in the suspensory ligament and 29.5% in the non-elite dressage horses. The conclusion was that a horse that performs in a specific sport gets injuries in a specific site, where the horses used for general purpose had a wider spread of injury sites. There was a high risk for the dressage horses to injure their suspensory ligament compared to the general purpose horses.

Murray *et al.* (2010) did a study based on a questionnaire that they had handed out to all members of British Dressage. 2554 horse owners answered whereof 80% were non-elite and 11% elite, the rest had not stated a performance level. They looked at risk factors for lameness. The study showed that horses which compete at the highest level, Grand Prix, had the highest percentage of lameness, 50% of the horses had in the last two years been lame. The second most common reason for lameness was injury in the suspensory ligament, 13% of the horses with lameness on a specific site, and a higher proportion of these were in the elite group.

Exercise and training

Butcher & Ashley-Ross (2002) looked at how the fetlock joint worked in Thoroughbred horses and if there was a difference with age. The result was that older horses have a stiffer suspensory apparatus and better shock absorption than young horses. They think that the young horses have immature tissue in the suspensory apparatus and may therefore not be ready to participate in race training.

Kasashima *et al.* (2008) did a study to see how exercise affected immature tendons in horses. Their conclusion was that pasture exercise in young horses would be enough to give tendons the load for it to get fully adapted. Extra exercise would not be harmful but would not either give extra strength to the tendons.

Smith *et al.* (1999) studied the tendons of different types of horses, young and old, and of different breeds. Their conclusion was that it is better to train and race young horses compared to older. The reason for this was that the immature tendons in the young horses are able to adapt and get stronger with exercise while the tendons in old horses have a very little ability to do that.

DISCUSSION

Everyone wants their horse to stay well and be free of injuries and a lot of people are interested in competitions, to show how well they have trained their horse. But as in all types of competition you want to push yourself further and further. Since a rider is not only pushing him-/herself to a higher level but the horse as well, he or she has a greater responsibility to make sure not to push it too far. Dressage riders want horses with good gait and will try to take them to high competition levels. Thoroughbred racehorse owners want their horses out on the track as early as possible since the classic races are for horses that are only three years old.

Lameness or decreased performance level caused by injury in the suspensory ligament can affect all types of horses and occur in all types of sports but it affect dressage horses to a larger extent (Murray *et al.*, 2010; Dyson *et al.*, 2006). Kasashima *et al.* (2004) found in their study of race horses that the risk of suspensory ligament desmitis increased with age. One hypothesis that they present is that this is because of an increased degeneration in the suspensory ligament but it takes further studies to verify that. Injuries to the superficial digital flexor tendon are the major problem for racehorses (Kasashima *et al.*, 2004). Since injuries to the suspensory ligament increase more with age this might be a bigger problem when the horse is at the end of its racing career.

In certain movements that are mandatory on high competition levels in dressage, like piaffe, passage and collected trot, the force that is put on the suspensory ligament is very high (Murray *et al.*, 2010; Holmstrom & Drevemo, 1997). Also young dressage horses with an extremely good gait have a greater risk to get proximal suspensory desmitis (Dyson, 2007). This might well be the reason why the suspensory ligament is so exposed to injury for these horses.

There are different opinions whether degenerative suspensory desmitis is a systemic disease or not. Halper *et al.* (2006) concluded that it is a systemic disease. They also refer to several human disorders that are similar to their description of the disease, suggesting it would be likely that it would occur in horses as well. However, the study by Schenkman *et al.* (2009) came to the conclusion that the proteoglycan accumulation was not the reason for the disease but rather a response to the injury that occurs. On the other hand Halper *et al.* (2011) claimed that this study did not get the same results as they got because of a different staining technique that could not detect all proteoglycans. However, if it is a systemic disease the question is why does the problem only show itself in the suspensory ligament and not in any of the other tissues that get the proteoglycan accumulation?

There are several theories concerning the age we should start training the horse and to what extent, to get a horse that has a higher chance to withstand injury. The studies I looked at all agree that tendons and ligaments are able to adapt to increasing loads in young horses. Without any exercise at all the tissues would become weak. However, they disagree on what amount and what type of exercise would be optimal for strengthening ligaments and tendons in the horse. Butcher & Ashley-Ross (2002) believe that you should not expose young horses

to race training at all. The suspensory ligament is not stiff enough and cannot give the fetlock joint the support that it needs with a rider on the back. In contradiction Smith *et al.* (1999) think that race training for young horses is good since they are able to adapt to the extra load while old horses are not. In between these suggestions lies the theory by Kasashima *et al.* (2008). They believe that pasture exercise is enough to strengthen the ligament but some training would not cause adverse effects.

The study done by Smith *et al.* (1999) was detailed; they used several horses in each group that got the same amount of training. They also used control groups and samples from wild horses. Everything is well documented and the results are listed. However, how they came to their conclusion is not clear. They state that keeping a young horse in a box with no exercise at all is the worst alternative for the ligament and tendon development and I do not think that anyone would disagree on that. They also say that too much exercise for the young horse would be harmful for these tissues and that a safe window is necessary. But in their final statement they do not mention one word about pasture exercised horses, only that a controlled exercise program for young horses would be the best and that it is better to race young horses rather than older. From what I could see in their results, when the paddock exercised horses were included, these were the horses that had the best tendons and ligaments. But one problem is that these horses were not included in all the different tests of the tendons and ligaments, or at least the results are not listed. Why it is like this is unknown but maybe just comparing box-rested horses with trained horses supported their theory, that early training and racing is to prefer, better. It should also be noted that the article is sponsored by the UK horserace betting levy board, and the conclusion that Smith *et al.* (1999) reached probably was in their interest.

Kasashima *et al.* (2008) had study two groups of horses in their, one that got pasture exercise four hours a day and one that got an additional exercise program. They could not see any significant differences between these groups and came to the conclusion that extra exercise is not harmful for the young horses. On the other hand you could from these results also state that extra exercise does not give more strength to the tendons and ligaments and therefore it is enough to have the young horses on pasture. This would probably be safer since no one seems to know where the upper limit for exercise of the young horse should be drawn.

For Butcher & Ashley-Ross (2002) it was not just the tendons and ligaments that were interesting but the whole fetlock joint. They claim that the reason for the high incidence of forelimb injury in the younger horses is because of the greater dorsiflexion and faster fetlock joint movement. According to them it occurs in the young horse because of their immature suspensory apparatus. Full-scale race training should not be introduced until the horse is musculoskeletally mature, which is around the age of four.

Overall you have to look at the whole horse and not just a single part to find out what is best for its development. And it seems that the safest way to keep the young horse is in a big paddock with shifting terrain and with horses of the same age to induce natural exercise.

REFERENCES

- Butcher, M.T. & Ashley-Ross, M.A. (2002). Fetlock joint kinematics differ with age in thoroughbred racehorses. *Journal of Biomechanics* 35(5), 563-571.
- Cunningham, D.J. (1883). The Development of the Suspensory Ligament of the Fetlock in the Foetal Horse, Ox, Roe-Deer, and Sambre-Deer. *J Anat Physiol* 18(Pt 1), i1-12.
- Davidson, E.J. Suspensory ligament desmitis. In: *Proceedings of Large animal proceedings of the North American Veterinary Conference, Orlando, Florida, USA, 17-21 January, 2009*. 2009. pp. 161-163: The North American Veterinary Conference.
- Dyson, S. (2002). Lameness and poor performance in the sport horse: Dressage, show jumping and horse trials. *Journal of Equine Veterinary Science* 22(4), 145-150.
- Dyson, S. (2007). Diagnosis and Management of Common Suspensory Lesions in the Forelimbs and Hindlimbs of Sport Horses. *Clinical Techniques in Equine Practice* 6(3), 179-188.
- Dyson, S., Murray R, R., Tranquille, C. & Adams, V. Association of type of sport and performance level with anatomical site of orthopaedic injury and injury diagnosis. In: *Proceedings of ESpoM Aachen 2006. Progress in Equine Veterinary Sports Medicine, 23-26 August 2006, Aachen, Germany*. 2006. pp. 653-654: Hippatrika Verlagsgesellschaft mbH. ISBN 0177-7726.
- Gibson, K.T. & Steel, C.M. (2002). Tutorial article - Conditions of the suspensory ligament causing lameness in horses. *Equine Veterinary Education* 14(1), 39-50.
- Halper, J., Khan, A. & Mueller, P.O.E. (2011). Degenerative Suspensory Ligament Desmitis - A New Reality. *Pakistan Veterinary Journal* 31(1), 1-8.
- Halper, J., Kim, B., Khan, A., Yoon, J.H. & Mueller, P.O. (2006). Degenerative suspensory ligament desmitis as a systemic disorder characterized by proteoglycan accumulation. In: *BMC Vet Res*. p. 12. England; 2). ISBN 1746-6148 (Electronic)1746-6148 (Linking).
- Holmstrom, M. & Drevemo, S. (1997). Effects of trot quality and collection on the angular velocity in the hindlimbs of riding horses. *Equine Vet J Suppl* (23), 62-5.
- Kasashima, Y., Takahashi, T., Birch, H.L., Smith, R.K.W. & Goodship, A.E. (2008). Can exercise modulate the maturation of functionally different immature tendons in the horse? *Journal of Applied Physiology* 104(2), 416-422.
- Kasashima, Y., Takahashi, T., Smith, R.K.W., Goodship, A.E., Kuwano, A., Ueno, T. & Hirano, S. (2004). Prevalence of superficial digital flexor tendonitis and suspensory desmitis in Japanese Thoroughbred flat racehorses in 1999. *Equine Veterinary Journal* 36(4), 346-350.
- Murray, R.C., Walters, J.M., Snart, H., Dyson, S.J. & Parkin, T.D.H. (2010). Identification of risk factors for lameness in dressage horses. *The Veterinary Journal* 184(1), 27-36.
- Rooney, J.R. (1986). Pathogenesis of three lesions causing lameness of the foreleg in horses. *Journal of Equine Veterinary Science* 6(6), 330-332.
- Schenkman, D., Armien, A., Pool, R., Williams, J.M., Schultz, R.D. & Galante, J.O. (2009). Systemic Proteoglycan Deposition Is Not a Characteristic of Equine Degenerative Suspensory Ligament Desmitis (DSLSD). *Journal of Equine Veterinary Science* 29(10), 748-752.
- Smith, R.K., Birch, H., Patterson-Kane, J., Firth, E.C., Williams, L., Cherdchutham, W., Weeren, W.R.v. & Goodship, A.E. Should equine athletes commence training during skeletal development?: changes in tendon matrix associated with development, ageing, function and exercise. In: *Proceedings of Equine exercise physiology 5. Proceedings of the Fifth International Conference on Equine Exercise Physiology, Utsunomiya, Japan, 20-25 September 1998*. 1999. pp. 201-209: Equine Veterinary Journal Ltd. ISBN 0425-1644.

- Soffler, C. & Hermanson, J.W. (2006). Muscular design in the equine interosseus muscle. *Journal of Morphology* 267(6), 696-704.
- Souza, M.V., Weeren, P.R.v., Schie, H.T.M.v. & Lest, C.H.A.v.d. (2010). Regional differences in biochemical, biomechanical and histomorphological characteristics of the equine suspensory ligament. *Equine Veterinary Journal* 42(7), 611-620.
- Stashak, T.S. (2001). Adams' Lameness in Horses. 5th edition. Williams & Wilkins. Page 620-624.
- Wilson, D.A., Baker, G.J., Pijanowski, G.J., Boero, M.J. & Badertscher, R.R. (1991). Composition and morphological features of the interosseous muscle in Standardbreds and Thoroughbreds. *American Journal of Veterinary Research* 52(1), 133-139.